Molluscum Contagiosum Associated with Acquired Immunodeficiency Syndrome: Experience in HIV outpatient care and literature review

Molusco contagioso associado à síndrome da imunodeficiência adquirida: experiência no atendimento em ambulatório de HIV e revisão da literatura

Paloma Marianni Suazo Encarnacion[1], Ivan Mauricio Herrera Garzon[1], Carlos José Martins[2,3], Ricardo Barbosa Lima[2,3], Fernando Raphael de Almeida Ferry[2,3]

ABSTRACT

Introduction: Molluscum contagiosum is a dermatosis caused by a DNA virus of the family Poxvirus and genus *Molluscipoxvirus*, affecting mainly children, sexually active adults, atopic individuals and immunocompromised patients, especially those with human immunodeficiency virus (HIV) infection. **Objective:** To describe our experience in caring for patients living with HIV who presented with extensive and severe *Molluscum contagiosum*, and to conduct a literature review on the subject as well. Methods: An electronic search was carried out in the MEDLINE/PubMed and SciELO databases and in the books: *ATLAIDS* and *AZULAY* limited to the period of January 2017 to June 2021**. Results:** Four clinical cases are reported in people living with HIV with extensive lesions normally not found in immunocompetent patients. The treatment performed in the cases reported in this article was the punctual application of 90% trichloroacetic acid (TCA) to each lesion, with complete remission of the clinical presentation in two patients over a period of three and six months. The other two patients did not receive treatment for molluscum contagiosum as they died because of pulmonary complications. **Conclusion:** Infection with *Molluscum contagiosum* in people living with HIV has disseminated forms with large-volume lesions, with substantial stigmatizing aesthetic impairment, and treatment with 100% TCA is quite effective.

Keywords: *Molluscum contagiosum*; acquired immunodeficiency syndrome, medication therapy management.

RESUMO

Introdução: Molusco contagioso é uma dermatose causada por um vírus de DNA da família poxvírus e do gênero *Molluscipoxvirus*. Afeta principalmente crianças, adultos sexualmente ativos, indivíduos atópicos e pacientes imunodeprimidos, especialmente aqueles com infecção pelo vírus da imunodeficiência humana (HIV). **Objetivo:** Descrever a experiência no atendimento de pacientes vivendo com HIV que apresentaram quadro de molusco contagioso extenso e grave, além de realizar uma revisão da literatura sobre o tema. **Métodos:** Foi realizada uma pesquisa eletrônica nas bases de dados MEDLINE/PubMed e SciELO e nos livros *ATLAIDS* e *AZULAY*, limitada ao período de janeiro de 2017 a junho de 2021. **Resultados:** São relatados quatro casos clínicos em pessoas que vivem com HIV com lesões extensas normalmente não encontradas em pacientes imunocompetentes O tratamento realizado nos casos relatados nesse artigo foi a aplicação pontual de ácido tricloroacético (ATC) 100% em cada lesão, com a remissão completa do quadro clínico em dois pacientes em um período de tempo entre três e seis meses. Os outros dois pacientes não receberam tratamento para o vírus do molusco contagioso pois evoluíram para óbito em razão de complicações pulmonares. **Conclusão:** A infecção pelo molusco contagioso em pessoas vivendo com HIV apresenta formas disseminadas com lesões de grande volume, com comprometimento estético estigmatizante importante, e o tratamento com ATC 90% é bastante eficaz.

Palavras-chave: molusco contagioso; síndrome da deficiência imunológica adquirida; conduta no tratamento medicamentoso.

INTRODUCTION

Molluscum contagiosum (MC) is a dermatosis caused by a DNA virus of the family Poxvirus and genus *Molluscipoxvirus*. Molluscum contagiosum virus (MCV) has four main subtypes, including MCV1, the most prevalent, and MCV2, which is more frequent in adults and is sexually transmitted in most cases [(1)].

It is a universal dermatosis that typically affects children, sexually active adults, atopic individuals and immunocompromised patients, especially those with human immunodeficiency virus (HIV) infection. Its transmission occurs by direct contact, self-inoculation and fomites. Typical lesions are papules, single or multiple, with a pearlescent appearance and presence of central umbilication, usually found on the face, trunk, extremities and genital areas [(1)].

In general, typical lesions are small papules on the skin with a shiny surface and central umbilication, however it should be noted that immunocompromised individuals may have variations and show atypical lesions, such as giant molluscum and follicular variations[(1)]. In this article, we review the current literature on MC and present four cases of patients with HIV and MC with atypical and extensive clinical manifestations, of which two were successfully treated and two died on admission because of other diseases.

OBJECTIVE

To describe our experience in caring for patients living with HIV who had extensive and severe MC, and to conduct a literature review on the subject as well. Through the bibliographic search, 51 articles were found, of which 14 were selected because they were directly

[1]Instituto de Pesquisa e Pós-Graduação Carlos Chagas – Rio de Janeiro (RJ), Brazil.
[2]Universidade Federal do Estado do Rio de Janeiro – Rio de Janeiro (RJ), Brazil.
[3]Hospital Universitário Gaffrée e Guinle – Rio de Janeiro (RJ), Brazil.

related to the purpose of the article; also, two books dealing with the subject were consulted. The treatment performed in the cases described was reported.

METHODS

At Hospital Universitário Gaffrée e Guinle, the immunology clinic serves approximately 2,500 patients with HIV/acquired immunodeficiency syndrome (AIDS). The patients reported in this article were seen in the period of 2010 to 2021, and the marked abundance of clinical lesions they presented with was what drew attention. Therefore, in this article, we decided to present four cases that called for their reporting in an open scientific journal on the internet, with the purpose of disclosing, in particular, the treatment performed with 90% trichloroacetic acid (TCA), which was fully effective.

The bibliographic survey was carried out through an electronic search in the MEDLINE/PubMed and SciELO databases with the descriptors, in English, Portuguese and Spanish, Molluscum Contagiosum, Acquired Immunodeficiency Syndrome Virus and Medication Therapy Management; also the books *ATLAIDS* and *AZULAY* were consulted. The search was limited to the period of January 2017 to June 2021, to select updated literature on MC disease.

DESCRIPTION OF CASES

Patient 1

A 46-year-old male with HIV for 18 years showed low adherence to the regular use of antiretroviral drugs and was undergoing treatment for disseminated tuberculosis. He had a T-CD4+ lymphocyte count of 1 cell/mm^3. Dermatological examination revealed the presence of a papular lesion, umbilicated in the central region, located in the right lower eyelid, with a rough appearance, in which multiple telangiectasias were observed (**Figure 1A**, highlighted in greater magnification in **Figure 1B**). A biopsy was performed and the material was sent for histopathological examination, which demonstrated the presence of large viral inclusion bodies within the cytoplasm, shifting the nucleus to the periphery (Henderson-Paterson bodies)[2,3]. We therefore concluded that this was a case of giant MC (**Figure 1C**). Despite the therapy instituted, the patient died as a result of pulmonary complications from tuberculosis.

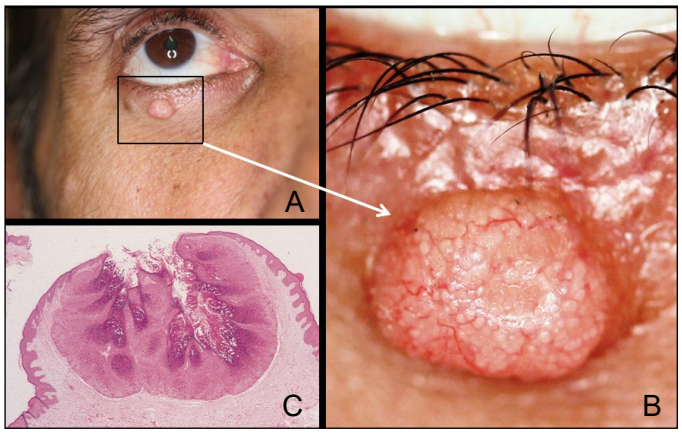

Source: Basílio-de-Oliveira[1].

Figure 1 – (A) Sessile papule, firm, with central umbilication in the lower eyelid region. On the right, at higher magnification, (B) we can see a lesion with central umbilication, a rough surface with the presence of telangiectasias. On the left, (C) there is a photograph of the histopathology of the lesion. Hematoxylin and eosin; 20x.

Patient 2

A 31-year-old male diagnosed as having AIDS for 5 years, without previous treatment, showed for 3 months multiple papular lesions of insidious development. On physical examination, bright papules with central umbilication were observed, spread on the face, also affecting the labial mucosa (**Figure 2A**). Laboratory tests revealed a T-CD4+ lymphocyte count of 100 cells/mm^3 and plasma HIV viral load of 130,000 copies/mL. Histopathological examination confirmed the diagnosis of MC, with findings similar to those described in patient 1. The proposed treatment was the prescription of zidovudine, lamivudine, and lopinavir/ritonavir, in addition to primary prophylaxis with sulfamethoxazole/trimethoprim (800/160 mg once a day) and azithromycin (1,500 mg per week). TCA (90%) was applied punctually to the lesions (Figure 2B). Gradual remission of the lesions was achieved (**Figures 2B and 2C**), with almost complete resolution of the condition after six months of treatment, resulting only in atrophic scars at the site (**Figure 2D**).

Patient 3

A 31-years-old female was HIV-positive for 13 years and showed low adherence to the use of antiretroviral therapy. Multiple papular lesions with an umbilical center were observed spread on the face (**Figures 3A and 3B**) and on the genitalia; they were not pruritic or painful, evolving over four months of. The T-CD4+ lymphocyte count

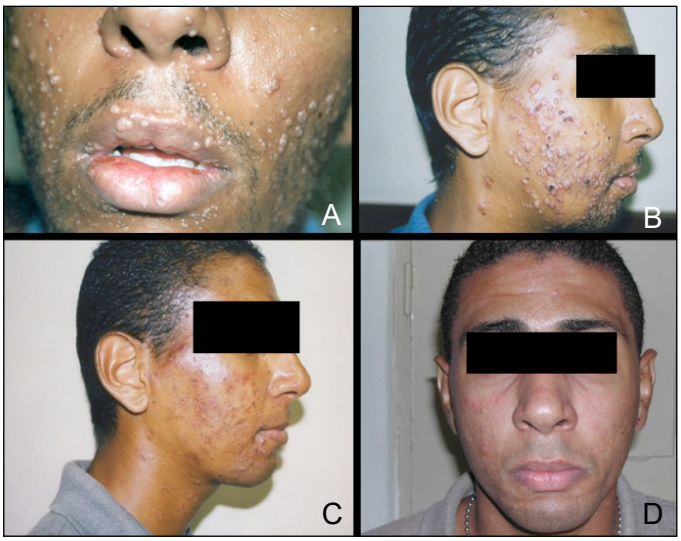

Source: Basílio-de-Oliveira[1].

Figure 2 – (A) Papulous lesions with central umbilication, spread on the face, non-pruritic and painless. (B and C) Photographs showing gradual satisfactory evolution of treatment with 100% trichloroacetic acid. (D) Almost complete resolution of lesions, showing small atrophic scars.

was 8 cells/mm^3, and the plasma HIV viral load was 405,000 copies/mL. A biopsy of one of the papules on the face confirmed the diagnosis of MC. Antiretroviral treatment was started with zidovudine, lamivudine and lopinavir/ritonavir and primary prophylaxis with sulfamethoxazole/trimethoprim (800/160 mg once daily) and azithromycin (1,500 mg per week). The lesions were initially treated with imiquimod on an outpatient basis, which resulted in an intense inflammatory reaction at the application sites and possible secondary infection (**Figure 3C**). The application of imiquimod was suspended, and amoxicillin with clavulanate and prednisolone was prescribed. After clinical improvement, treatment was started with 100% TCA, with good gradual evolution and complete resolution of the lesions within 10 months (**Figure 3D**).

Patient 4

A 52-year-old male, newly diagnosed with AIDS, with a T-CD4+ lymphocyte count of 4 cells/mm^3 presented with severe wasting syndrome (slim disease) (**Figure 4A**), showing showing lesions with histopathological diagnosis of MC in the right dorsolateral region (**Figure 4B**), in the face (**Figure 4C**, with details of the lesion in **Figure 4D)** and in the anterior region of the neck (**Figure 4E**). He was diagnosed with disseminated tuberculosis, particularly affecting the liver, progressing to death after nine days of hospitalization.

Source: Basílio-de-Oliveira[1].

Figure 3 – Multiple papular lesions on the face, non-pruritic, painless, (A and B) especially affecting the nasolabial region. After application of imiquimod, (C) there was severe inflammation of the lesions, with signs of secondary infection. After adequate treatment, the application of trichloroacetic acid was started, with good evolution. Eighteen months later, the patient displayed (D) almost complete resolution of the lesions, with atrophic scars.

DISCUSSION

MC is a dermatosis caused by a double-stranded DNA virus[1] of the family Poxvirus and genus *Molluscipoxvirus*. MCV has four different genotypes: MCV1, MCV2, MCV3 and MCV4[4,5]. The emphasis is on the first two: MCV1 is the most prevalent, and MCV2, which is more frequent in adults, is usually sexually transmitted and causes genital lesions[6].

MC is a universal dermatosis that typically affects children, sexually active adults, atopic individuals and immunocompromised patients, especially those with HIV infection. Virus transmission occurs through direct skin-to-skin contact, self-inoculation and fomites, and it is also a sexually transmitted disease[4,7-9]; but it can be located in any part of the body[10]. However, the lesions are rarely located on the palms of the hands or the soles of the feet or on mucous membranes such as lips, oral mucosa and conjunctiva[11]. The incubation period can range from a week to several months after contact([10].

Source: Basílio-de-Oliveira[1].

Figure 4 – (A) Serious wasting syndrome (slim disease). Lesions with a histopathological diagnosis of MC can be seen in (B) right dorsolateral region, (C) on the face, (D) with details of the lesion and (E) in the anterior region of the neck.

In recent years, studies related to *Molluscum contagiosum* have evolved greatly in all aspects of the virus. These viruses average 300 × 210 nm and are brick-shaped, and they develop in the cytoplasm of epidermal keratinocytes. The lesion observed under a light microscope is characterized by large cells with infiltration of eosinophilic viral material (Henderson-Paterson bodies) that displace the nucleus to the periphery[6,9,12]. The virus has a structure formed by lipids and produces proteins (chemokine analogue, glutathione peroxidase analogue and caspase inhibitor)[10] that have the ability to protect the infected cell from the immune system and prevent its elimination[9]. The continuous replication of MCV in the epidermis and its property to resist immune defense mechanisms induce the formation of local benign tumors characteristic of the disease. In patients with HIV, the histological features can be atypical, uncommon and with giant and pedicled pseudocystic variants[6].

The diagnosis is mainly clinical, where the typical lesions are represented by single or multiple papules, pearly and umbilicated in the center[4-6], skin-colored, generally measuring 3 to 5 mm[10]. However, the use of a dermatoscope can help to better visualize the characteristic lesions and contribute to the diagnosis[10,11]. Biopsy is indicated in occasions when the diagnosis is not clear[4,9]. An example is patients with HIV, who often have atypical features of the disease.

Lesions are usually located on the face, neck, back and arms, especially in children. Genital and pubic lesions are common in sexually active patients[6]. It should be emphasized that, in immunocompromised individuals, the occurrence of atypical clinical forms is common, with emphasis on the disseminated, persistent and giant forms, and in some cases, the characteristic central umbilication is not observed, which makes its recognition difficult.

MC is a benign and generally self-limiting disease. Lesions can persist for more than six months and then disappear spontaneously. Lesions that spread by self-inoculation can persist for up to 8 to 12 months[10,11]. In immunocompromised patients, lesions may persist for a longer period and could even resist local treatment.

In immunocompetent patients, MC can be confused with common warts, syringomas, pyoderma, papular granuloma annulare or condyloma acuminata[10]. In the early stages of the disease, when the lesion is very small, it can be confused with the varicella zoster

Table 1 – Molluscum contagiosum treatments.

Treatment	Protocol	Secondary effects
Physical procedures		
Curettage	Lesions removed with a curette after topical anesthesia	Anxiety, pain, bleeding, scars
585-nm pulsed dye laser	Single pulse delivered to each lesion (duration 0.45 ms; spot diameter=7 mm; energy density 6–7 J/cm^2) after topical anesthetic; repeated after 2-3 weeks if necessary	Pain, purpura, itching
Photodynamic therapy*	Lesions cleaned with acetone, application of 5-aminolevulinic acid photosensitizer; 14–24 h later, drug activated with short-wavelength light source for 16 min	Erythema or edema, blistering, pigment changes, pain, burning, itching
Electron beam therapy*	9- to 12-MeV electron beams directed at the lesion sites (large or severe) five times a week, up to 18 treatments per site, for a total radiation dose of up to 4,560 cGy	Erythema, pigment changes
Destructive chemical agents		
10% phenol	Direct application to lesion	Scars
100% trichloroacetic acid	Direct application to lesion	Erythema and hypopigmentation
Non-destructive chemical agents		
0.9% cantharidin	Apply to the lesion and wash after 4 h	Skin blisters, erythema, itching
0.3-0.5% podophyllotoxin	Apply twice a day for 3 days	Erythema and itching
12% salicylic acid gel	Apply to the lesion once or twice a week for 4 weeks	Punches
10% benzoyl peroxide cream	Apply to the lesion twice a day for 4 weeks	Moderate dermatitis
0.5% retinoic acid cream	Apply to the lesion twice a day for 4 weeks	Moderate dermatitis
5-10% aqueous potassium hydroxide	Apply to each lesion twice a day until signs of inflammation or ulceration appear	Punches, depigmentation
Immunomodulators		
5% imiquimod cream	Apply to lesions for 8 h at night and wash; apply 3 to 5 times a week until clinical cure	Erythema, ardor, itching
Cimetidine	40 mg/kg/day in 2-3 divided doses, for 2 months	Potential drug interactions
Intralesional Candida antigen	0.3 mL of Candida antigen injected with a 1-mL syringe and 30G needle directly into individual papules	Pain
Diphencyprone	0.001-2% in lesions twice a week for up to 2 months	Erythema, depigmentation, blistering, itching
Antiviral agents		
1-3% cidofovir cream	Apply 1% cidofovir to each lesion once daily 5 times a week for 8 weeks or 3% cidofovir to each lesion once daily 5 times a week for 2 weeks	Erythema Burning Pain Itching
Intravenous cidofovir	3-5 mg/kg per week for 2 weeks; followed by infusions over a week, complete 4-9 infusions until clinical improvement.	Nephrotoxicity Neutropenia

*Lesions cleaned with acetone, application of 5-aminolevulinic acid-based photosensitizer; 14–24 h later, drug activated with short-wavelength light source for 16 min. Source: Leyva-Sartori[10] and Chen et al.[11].

virus or with flat warts. In patients with HIV, the main differential diagnosis is with histoplasmosis or cutaneous cryptococcosis [11].

TREATMENT

The prevalence of MC in patients with HIV infection ranges from 5 to 18% compared to 1% in the seronegative population. In some situations, patients may be refractory to treatment, especially when the T-CD4+ lymphocyte count is less than 200 cells per mm^3. Even so, MCV lesions can occur at any stage of HIV infection[13].

Several methods for the treatment of MC have been described in the literature (**Table 1**), including: physical destruction with cryotherapy, extraction by curettage or puncture with a needle, topical agents such as tretinoin, tazarotene, salicylic acid, TCA, imiquimod, potassium hydroxide, podophyllin or phenol and contact immunotherapies. Due to their antiviral and systemic immunomodulation effects, systemic treatments such as cimetidine and antivirals (cidofovir and interferon) have been suggested as a treatment modality in immunosuppressed patients with severe or refractory disease. Interferon alpha (which is a pro-inflammatory cytokine) can be administered subcutaneously or intralesional[5].

Recently, intralesional immunotherapy with the measles-mumps-rubella (MMR) vaccine has been extensively tried[14]. It is suggested that the MMR vaccine is effective on the basis of cell-mediated immunity acting in the pathogenesis of MC[14].

In patients with HIV, the initiation of antiretroviral therapy can lead to the resolution of lesions caused by MCV, mainly because of the increase in the T-CD4+ lymphocyte count. In patients with HIV, the treatment of choice for MC is curettage for smaller lesions, which may or may not be followed by chemical cauterization with 90% TCA or electrocauterization[13]. However, there is no universally recommended therapy for the resolution of MC in HIV patients[5].

The treatment performed in the patients reported in this article was the punctual application of 90% TCA, with complete remission of the lesions in two patients within a period of three or six months. The other two patients did not receive treatment for MCV as they died from pulmonary complications.

TCA is used as a treatment for numerous skin conditions. Its use results in a type of chemical peeling, which causes the removal of the epidermis or altered dermis in a controlled manner, with the removed skin layer being replaced by new cells[13]. TCA is one of the most versatile agents used in chemical peels because of its ability to provide skin exfoliation at different depths (depending on its concentration), as it is stable and non-toxic[13].

Finally, the various methods described in the literature prevent an accurate indication of a treatment of choice. Treatment, therefore, varies according to the protocol of each institution and the experience of each professional who performs the procedure. In our cases, the treatment of choice was TCA, with excellent results.

Strengths

As strengths, we report the wealth of clinical cases, the findings in the literature and the effectiveness of the treatment performed.

Limitation

The number of cases was small, but they had robust documentation.

CONCLUSION

The clinical presentation of MC in HIV-immunosuppressed patients causes typical extensive and severe lesions. The treatment performed on the patients reported in this article was the punctual application of 90% TCA, with complete remission of the lesions in two patients within three and six months.

Approval by the Human Research Ethics Committee

During hospitalization, patients signed an informed consent form allowing the reporting of cases in articles and conferences, as well as the use of their images. They also signed a form authorizing the use of their images in scientific productions. As the patients involved were not part of a research study, approval by the ethics committee was not required.

Participation of each author

Paloma Mariann Suazo Encarnacion: Literature review and article writing.

Ivan Mauricio Herrera Garzon: Literature review and article writing.

Carlos José Martins: He carried out the treatment and clinical monitoring of the evolution of the lesions.

Ricardo Barbosa Lima: He carried out the treatment and clinical follow-up of the evolution of the lesions.

Fernando Raphael de Almeida Ferry: He prepared the article, took the photographs of the patients, described the clinical cases and carried out the treatment of HIV in these patients.

Funding

There were no funding sources for this study.

Conflict of interests

All authors had access to all study data and assume responsibility for the validity of findings. None of the authors or collaborators have conflicts of interest related to this article to disclose.

REFERENCES

1. Basílio-de-Oliveira CA. ATLAIDS: Atlas de patologia da síndrome da imunodeficiência adquirida (Aids/HIV). Casos clínicos. 2ª ed. São Paulo: Atheneu; 2015.
2. Henderson W. Notice of the Molluscum Contagiosum. Edinb Med Surg J. 1841;56(148):213-8.
3. Paterson R. Cases and observations on the Molluscum Contagiosum of Bateman, with an account of the minute structure of the tumours. Edinb Med Surg J. 1841;56(148):279-88.
4. Meza-Romero R, Navarrete-Dechent C, Downey C. Molluscum contagiosum: an update and review of new perspectives in etiology, diagnosis, and treatment. Clin Cosmet Investig Dermatol. 2019;2019(12):373-81. https://doi.org/10.2147/CCID.S187224
5. Paudel V, Chudal D. Oral isotretinoin therapy in recalcitrant Molluscum

contagiosum in an immunocompromised patient. Case Rep Dermatol Med. 2021;2021:5529382. https://doi.org/10.1155/2021/5529382
6. Edwards S, Boffa MJ, Janier M, Calzavara-Pinton P, Rovati C, Salavastru CM, et al. 2020 European guideline on the management of genital molluscum contagiosum. J Eur Acad Dermatol Venereol. 2021;35(1):17-26. https://doi.org/10.1111/jdv.16856
7. Guerrero-Álvarez A, Zavala-Manzanares JA, Estrada-Aguilar L. Molusco contagioso: un reto diagnóstico en pacientes inmunosuprimidos. Rev Mex Dermatol. 2021;65(1):102-4. https://doi.org/10.24245/dermatolrevmex.v65i1.5058
8. Achdiat PA, Rowawi R, Fatmasari D, Karisa NA, Dwipangestu G, Avriyanti E, et al. Case series: experience of using 20% potassium hydroxide solution to treat adult sexually transmitted Molluscum Contagiosum. Clin Cosmet Investig Dermatol. 2020;2020(13):671-6. https://doi.org/10.2147/CCID.S270380
9. Rodríguez G, Arenas D. Molusco contagioso. Rev Asoc Colomb Dermatol Cir Dematol. 2019;25(4):304-13. https://doi.org/10.29176/2590843X.304
10. Leyva-Sartori M. Molusco contagioso. Dermatol Peru. 2017;27(3):156-60. Available at: https://www.dermatologiaperuana.pe/assets/uploads/revista_59mk_03_articulo_revision_rev_derma_27-3.pdf
11. Chen X, Anstey AV, Bugert JJ. Molluscum contagiosum virus infection. Lancet Infect Dis. 2013;13(10):877-88. https://doi.org/10.1016/S1473-3099(13)70109-9
12. Molina L, Romiti R. Molusco contagioso em tatuagem. An Bras Dermatol. 2011;86(2):352-4. https://doi.org/10.1590/S0365-05962011000200022
13. Azulay R, Azulay D, Azulay-Abulafia L. Dermatologia. 7ª ed. Rio de Janeiro: Guanabara Koogan; 2017.
14. Chauhan P, Jindal R, Meena D. Intralesional measles, mumps, and rubella vaccine immunotherapy in molluscum contagiosum: a retrospective observational study from a tertiary care center in north India. Dermatol Ther. 2021;34(1):e14615. https://doi.org/10.1111/dth.14615

Address for correspondence:
FERNANDO RAPHAEL DE ALMEIDA FERRY
Hospital Universitário Gaffrée e Guinle
Rua Mariz e Barros, 775 – Tijuca
CEP: 20270-901
Rio de Janeiro (RJ), Brazil
E-mail: ferry@unirio.br

Received on: 10.25.2021
Approved on: 11.12.2021

This is an open access article distributed under the terms of the Creative Commons license.