Chlamydia infection resembling ulcerative colitis: case report

Infecção por clamídia lembrando retocolite ulcerativa: relato de caso

Dario Palhares[1]

ABSTRACT

Introduction: The diagnosis of ulcerative colitis is relatively complex because the symptoms are similar to those seen in several other diseases. **Objective:** To report a case of rectal chlamydial infection whose initial symptoms resembled ulcerative colitis. **Case report:** A 50-year-old male patient presented with diarrhea, blood and mucus in the stools, and an ulcer in the rectum. The histopathological exam pointed to chronic, unspecified inflammation. After a broad serological screening, with Immunoglobulin M positive for *Chlamydia* and a high titer of immunoglobulin G, the patient was treated with antibiotics and is clinically cured. Later, he remained Immunoglobulin M positive, but the titers of immunoglobulin G lowered considerably. *Chlamydia* has been shown to live in the gut microbiota, which could explain the case. **Conclusion:** It is important to search for chlamydial infection as a differential diagnosis of ulcerative colitis.

Keywords: Azithromycin. Tetracycline. Doxycycline. Colonoscopy. Inflammatory bowel disease. Sexually Transmitted Diseases.

RESUMO

Introdução: A retocolite ulcerativa é uma condição clínica de diagnóstico relativamente complexo, uma vez que apresenta sinais e sintomas comuns a muitas outras doenças. **Objetivo:** Relatar um caso de infecção anorretal por clamídia, cujos sintomas iniciais se pareciam com os de retocolite ulcerativa. **Relato de caso:** Paciente de 50 anos, do sexo masculino, apresentou-se com diarreia, muco e sangue nas fezes, e úlcera no canal anorretal. O exame histopatológico mostrou um processo inflamatório crônico e inespecífico, então procedeu-se a amplo rastreamento sorológico, que revelou Imunoglobulina M positivo para clamídia e altos títulos de Imunoglobulina G. O paciente foi tratado com antibióticos e encontra-se clinicamente curado. No seguimento, permanece com Imunoglobulina M positivo, mas os títulos de Imunoglobulina G decresceram consideravelmente. Bactérias do gênero *Chlamydia* têm sido reportadas como parte da microbiota intestinal, o que poderia explicar tal comportamento sorológico. **Conclusão:** É importante rastrear por clamídia como diagnóstico diferencial das suspeitas de retocolite ulcerativa.

Palavras-chave: Azitromicina. Tetraciclina. Doxiciclina. Colonoscopia. Doenças Intestinais Inflamatórias. DST.

INTRODUCTION

Ulcerative colitis is an inflammatory bowel disease presentation associated with a disorder in the immune system[1,2]. The main clinical symptoms are diarrhea, tenesmus, evacuation urgency, and blood and mucus in the stools. This clinical condition is chronic and can cause several intestinal and nutritional complications, and lesions in other organs[1,2]. On histopathological examination, ulcerative colitis is shown as a diffuse inflammation restricted to the mucosal and submucosal layers occurring only in the colon and rectum[1,2]. Lesions varying from erosions on the mucosa layer to commitment of the muscular layer can be observed. The presence of polyps and pseudopolyps is also common[1,2].

The diagnosis is complex and is a result of a set of clinical manifestations and their temporal evolution, laboratory evaluations, and biopsies. No hallmark is used to confirm or rule out the diagnosis[1,2]. Similarly, the differential diagnosis is very complex, since the most frequent symptoms of ulcerative colitis are the same as those observed in several other diseases[3].

We report a clinical case in which the initial, more probable diagnostic hypothesis was ulcerative colitis, but in the end, it showed to be a *Chlamydia* rectal infection. The treatment of ulcerative colitis includes aminosalicylates, corticoids, immunosuppressants, and, more recently, immunobiological agents, but some patients only find relief after the surgical removal of the colon and rectum[1,3]. At the same time, *Chlamydia* is an infectious disease curable by the correct use of antibiotics[4,5].

[1]Universidade de Brasília, Olympic Center – Brasília (DF), Brazil.

OBJECTIVE

To report a case of chronic diarrhea and anorectal ulcer whose final diagnosis was anorectal chlamydial infection.

CASE REPORT

Male patient, 50 years old, 1.80 m, 77 kg, normotensive, previously healthy. He referred to a daily intestinal rhythm of one or two dejections per day, but suddenly he could not evacuate for about seven days when, finally, he started to present with a daily intestinal rhythm of three to five dejections, most of them with blood and mucus. He noticed blood in the stools every day, but not on all dejections. The physical exam was normal, and the anoscopy did not show hemorrhoids, fissures, or ulcers. The patient underwent biochemical blood exams, with normal results. He was negative for HIV and VDRL. The parasitological stool examination revealed *Blastocystis hominis*, treated with nitazoxanide. Further exams did not show protozoans nor worms, but the symptoms remained. Upper digestive endoscopy was normal, and negative for *Helicobacter pylori*. Colonoscopy showed a sessile polyp of 5 mm in diameter in the sigmoid colon. The histopathological exam showed a mucosa layer with intense inflammatory activity and polyp with no abnormal cells. He started using mesalamine suppositories, which reduced mucus on the stools, but blood persisted. Hemogram was normal, with 6,100 leukocytes/mL (53% segmented, 7% eosinophils, 1% basophils, 34% lymphocytes, 5% monocytes). Protein C was 4.88 mg/dL (limit for inflammation: 5.00 mg/dL). Negative to antinuclear factor, anti-DNA, and tissue antitransglutaminase. Negative to the tumoral

markers: CEA, CA 125, CA19/9, and alpha-fetoprotein. Fecal pH was 6.0, negative for fecal leukocytes and fat. Fecal calprotectin was 289 mcg/g (reference: lower than 50 mcg/g). After six months of using mesalamine, he underwent a new colonoscopy that revealed one ulcer in the border between the anus and the rectum and a diffuse proctitis (**Figure 1**). The biopsy showed a regular organization of the tissues, with mononuclear inflammatory infiltrate in the lamina propria and no lymphocytic infiltrate in the epithelium. Immunohistochemistry was negative for cytomegalovirus, herpesvirus, and Epstein-Barr's virus. The patient was then referred to a more detailed screening for infectious diseases. At ten months of clinical evolution, the exams were negative for HIV, VDRL, anti-treponemal antibodies, hepatitis C, and anti-gonococcal antibodies. Immune pattern to hepatitis A and susceptible to hepatitis B, referred to vaccination against hepatitis B. PPD skin test for tuberculosis was nonreactive (0 mm). The urinary search for *Chlamydia* and gonococcus was negative. Serology was strongly reactive against *Chlamydia trachomatis*: IgG was more than 250 U/mL (reference: 15.0 U/mL) and IgM was 19.3 U/mL (reference 14.0 U/mL). Coincidently, while he waited for the blood test results, he underwent a dental treatment in which he took azithromycin for five days, with complete remission of the symptoms. When he got the results, he underwent additional treatment with doxycycline for seven days. After one year of follow-up, no more symptoms were reported. However, at an annual checkup, serology against *Chlamydia* remained IgM positive (19.0 U/mL, similar to the time of diagnosis) but IgG titers had lowered to 78 U/mL).

DISCUSSION

At the beginning of the clinical investigation, the main diagnostic hypothesis was ulcerative colitis. The clinical symptoms and the presence of a polyp were compatible with this hypothesis, and the markers of intestinal inflammation were positive, notably fecal calprotectin. However, the histopathological exam at month six of evolution did not show elements commonly seen in ulcerative colitis, such as neutrophilic infiltrate in the mucosal and submucosal layers; mucosal edema, focal hemorrhage, and depletion of mucus[1,3]. Instead, the exam showed a chronic inflammatory process pointing out a secondary cause of proctitis. Immuno-histochemistry screened for three common viruses, but in the end, the final diagnosis was serological.

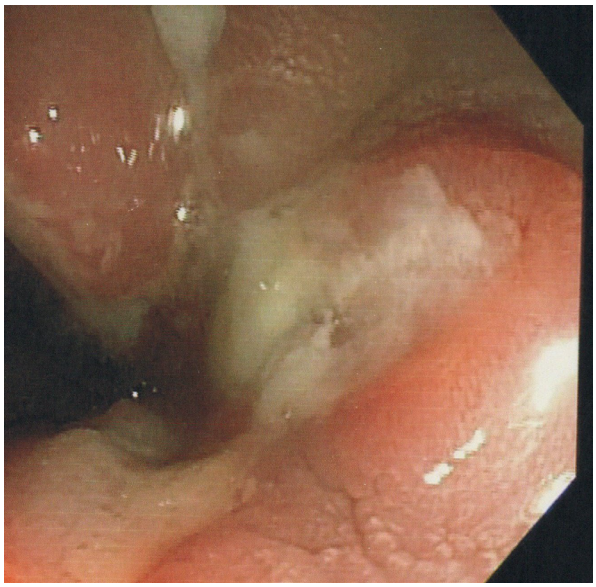

Figure 1 – Presence of an ulcer in the transition between the rectum and the anus, as observed and biopsied after six months from the beginning of the clinical symptoms. It was later revealed to be caused by Chlamydia trachomatis infection.

The serological diagnosis of *Chlamydia trachomatis* may not be accurate enough to differentiate an acute infection from simply immune memory[6]. In this way, the serological screening of chlamydial infection has different purposes between a broad epidemiological survey and a particular approach to a given patient[6]. In the present case, the pattern of other serological tests, the presence of IgM despite the long clinical evolution, and the high titer of IgG against *Chlamydia* that was reduced after treatment were the elements that confirmed the diagnosis of rectal chlamydial infection[6,7].

Regarding the serological follow-up, in a cohort studied by Henry-Suchet et al.[7], about one-fourth of the patients remained positive for anti-chlamydia IgM after proper treatment. Out of these, half showed symptoms and/or positiveness to *Chlamydia* culture and the other half was asymptomatic with no detection of *Chlamydia*. In the present case, since IgG titers had lowered substantially, the conclusion was that there was no active infection, so the patient was likely to be in the group of one-eighth of patients who remain IgM positive for a longer time, as the decrease in IgG titers is considered to be the cure of chlamydial infection[6,7]. Some patients still show high IgG titers even after proper treatment, with no detection of active chlamydia infection[6,7]. However, if that was the case, the cure would not be ascertained.

Compared to 1833, when venereal lymphogranuloma was described for the first time in clinical practice[8], the taxonomical classification of the bacteria of the family Chlamydiaceae has changed a lot, especially over the last ten to fifteen years, with protein and molecular markers[9-11] Currently, this family is considered to be comprised of a single genus – *Chlamydia* – with 16 obligatory intracellular parasite species. Two species, *C. trachomatis* and *C. pneumoniae*, infect humans, causing conjunctivitis (and subsequent blindness), pneumonia (and subsequent death), and anogenital inflammation (and subsequent infertility). *Chlamydia trachomatis* is subdivided into three biovars, according to the disease it causes (conjunctivitis, venereal lymphogranuloma, or unspecific anogenital inflammation)[9-11]. The biovars are subdivided into serovars according to the occurrence of certain major outer membrane protein complexes, totaling 13 genotypes. The serovars L1 to L3 cause venereal lymphogranuloma; the serovars A to C cause conjunctivitis, and the serovars D to K cause anogenital inflammation, which is frequently asymptomatic or with mild symptoms[9-11]. That is, a large portion of *Chlamydia*-infected patients will show mild or no symptoms. Therefore, it is highly probable that in the case shown herein, the patient was infected with one of the D-K serovars.

Being an intracellular parasite, the diagnosis via culture is complex, as not all laboratories of clinical analysis are equipped to do so[1,8]. However, with the appearance of diagnostic resources based

on antigenic and molecular markers (predominantly, Nucleic Acid Amplification Tests (NAATs)), several epidemiological screenings have been carried out, showing a prevalence of 5 to 20% according to the population sampled[12-16]. Anyway, this test has not yet been as widely adopted as it could be. Therefore, in the present case, the second rectal biopsy searched for some viruses, but did not search for *Chlamydia*. That is, among the sexually transmitted infections, *Chlamydia trachomatis* shows sharp geographical differences, but it occurs with a considerable frequency and should be screened more routinely in daily clinical practice. Therefore, although it is known that *Chlamydia* antibody tests have shown false positive and false negative results[17,18] and do not differentiate a current infection from immunological memory, Tosic-Pajic et al.[18] consider the serological tests to be the most suitable screening method in terms of cost-effectiveness.

Regarding the manifestations of an anogenital infection by *Chlamydia trachomatis*, there is a dissociation between genital and anorectal manifestations, that is, some women present with cervicitis/endometritis/salpingitis only, proctitis only, or both; and some men present with urethritis/prostatitis only, proctitis only, or both[15,16]. In the epidemiological screenings where the sexual practices were questioned, the practice of anal sex could not be associated with the infectious focus, that is, a significant portion of the patients deny this practice but present with proctitis, and a significant portion report this practice but present with genital infection only[14,15].

The treatment of *Chlamydia trachomatis* infection is done with macrolides or tetracyclines, and quinolones have shown some efficacy[4,5]. The beta-lactams reduce infectivity and the speed of replication of *C. trachomatis*, but they are not very effective in its eradication, and when the patient stops taking them, a strain resistant to macrolides can grow[5]. There is the description that a single dose of 1g of azithromycin can eradicate *Chlamydia* infections, but the therapeutic failure rate, of about 20%, points out that this strategy can induce antimicrobial resistance in a relatively short time[4,5]. For mild anorectal infections, Hocking et al.[5] recommend at least seven days of antibiotics, while for more extensive forms of venereal lymphogranuloma, the use of antibiotics needs to be extended to three weeks or more.

Rank et al.[19] state that in mammals and birds, Chlamydiaceae species may remain silently in the gut. Therefore, in humans, *Chlamydia* would live in the cecum, hence not being subjected to complete eradication, which could explain the rates of reinfection (about 3% of the patients) and perhaps the persistence of IgM titers for a long period. However, this aspect needs to be studied and understood more deeply in human patients.

Strengths: The case is well documented regarding the screening of differential diagnosis.

Limitation: The diagnosis was made based on serological testing and on the response to the treatment; ideally, the diagnosis would be confirmed by antigenic and/or molecular testing.

CONCLUSION

In conclusion, the case reported herein points out that in the differential diagnosis of inflammatory bowel disease, the search for *Chlamydia* infections should be reinforced, as it has been commonly done with other chronic infectious diseases.

Approval by the Human Research Ethics Committee

Consubstantiated opinion report Plataforma Brasil CAAE 59032521.4.0000.8927

Funding

The author declares no financial support.

Conflict of interest

The author declares no conflict of interest.

REFERENCES

1. Maranhão D, Vieira A, Campos T. Características e diagnóstico diferencial das doenças inflamatórias intestinais. J Bras Med. 2015;103(1):9-15.
2. Tontini GE, Vecchi M, Pastorelli L, Neurath MF, Neumann H. Differential diagnosis in inflammatory bowel disease colitis: state of the art and future perspectives. World J Gastroenterol. 2015;21(1):21-46. https://doi.org/10.3748/wjg.v21.i1.21
3. Brasil. Protocolo clínico e diretrizes terapêuticas da retocolite ulcerativa. Brasília: Ministério da Saúde – Conitec; 2020. 64p.
4. World Health Organization. Guidelines for the treatment of Chlamydia trachomatis. Geneva: WHO; 2016. 54p.
5. Hocking JS, Kong FY, Timms P, Huston WM, Tabrizi SN. Treatment of rectal chlamydia infection may be more complicated than we originally thought. J Antimicrob Chemother. 2015;70(4):961-4. https://doi.org/10.1093/jac/dku493
6. Woodhall SC, Gorwitz RJ, Migchelsen SJ, Gottlieb SL, Horner PJ, Geisler WM, et al. Advancing the public health applications of Chlamydia trachomatis serology. Lancet Infect Dis. 2018;18(12):e399-407. https://doi.org/10.1016/S1473-3099(18)30159-2
7. Henry-Suchet J, Askienazy-Elbhar M, Thibon M, Revol C, Akue BA. Post-therapeutic evolution of serum chlamydial antibody titers in women with acute salpingitis and tubal infertility. Fertil Steril. 1994;62(2):296-304. https://doi.org/10.1016/s0015-0282(16)56882-4
8. Neves RG, Santos OLR. Linfogranuloma venéreo – 160 anos de progressos clínicos e laboratoriais. J Bras Doenças Sex Trans. 1996;8(2):34-40.
9. Elwell C, Mirrashidi K, Engel J. Chlamydia cell biology and pathogenesis. Nat Rev Microbiol. 2016;14(6):385-400. https://doi.org/10.1038/nrmicro.2016.30
10. Pannekoek Y, Qi-Long Q, Zhang Y, Ende A. Genus delineation of Chlamydiales by analysis of the percentage of conserved proteins justifies the reunifying of the genera Chlamydia and Chlamydophila into one single genus Chlamydia. Pathog Dis. 2016;74(6):ftw071. https://doi.org/10.1093/femspd/ftw071
11. Phillips S, Quigley BL, Timms P. Seventy Years of Chlamydia Vaccine Research - Limitations of the Past and Directions for the Future. Front Microbiol. 2019;10:70. https://doi.org/10.3389/fmicb.2019.00070
12. Castro CR, Passos MRL, Pinheiro V, Barreto NA, Rubenstein I, Santos C. Detection of Chlamydia trachomatis in military men with clinical complaints of urethritis. J bras Doenças Sex Transm. 2000;12(3): 4-11.
13. Frias MCAA, Pereira CFA, Pinheiro VMS, Pinheiro MS, Rocha CF. Frequency of Chlamydia trachomatis, Urealplasma urealyticum and Mycoplasma hominis in endocervix of women during menacme. J Bras Doenças Sex Transm. 2001;13(2):5-22.
14. Marques CA, Menezes M, Coelho I, Marques CR, Celestino L, Melo M, et al. Genital infection by Chlamydia trachomatis in couples attending in conjugal sterility ambulatory. J Bras Doenças Sex Transm. 2007;19(1):5-10.
15. Jin F, Prestage GP, Mao L, Kippax SC, Pell CM, Donovan B, et al. Incidence and risk factors for urethral and anal gonorrhoea and chlamydia in a cohort of HIV-negative homosexual men: the Health in Men Study. Sex Transm Infect. 2007;83(2):113-9. https://doi.org/10.1136/sti.2006.021915
16. Llata E, Braxton J, Asbel L, Chow J, Jenkins L, Murphy R, et al. Rectal chlamydia trachomatis and Neisseria gonorrhoeae infections among women reporting anal intercourse. Obstet Gynecol. 2018;132(3):692-7. https://doi.org/10.1097/AOG.0000000000002804

17. Katz Z, Levy R, Lurie S. Positive serology for chlamydia: is it always for Chlamydia trachomatis? Gynecol Obstet Invest. 1995;39(4):271-3. https://doi.org/10.1159/000292424
18. Tosic-Pajic J, Sazdanovic P, Sorak M, Cukic J, Arsovic A, Milovanovic D, et al. Chlamydia trachomatis screening in resource-limited countries - Comparison of diagnostic accuracy of 3 different assays. J Infect Dev Ctries. 2018;12(9):733-40. https://doi.org/10.3855/jidc.10442.
19. Rank RG, Yeruva L. Hidden in plain sight: chlamydial gastrointestinal infection and its relevance to persistence in human genital infection. Infect Immun. 2014;82(4):1362-71. https://doi.org/10.1128/IAI.01244-13

Address for correspondence
DARIO PALHARES
Superquadra Sul, 416 – Asa Sul
Brasília (DF), Brazil
CEP: 70299-090
E-mail: dariompm@unb.br

Received on: 06.16.2022
Approved on: 07.14.2022

This is an open access article distributed under the terms of the Creative Commons license.