Clinical manifestations of syphilis in the oral cavity: a review

Manifestações clínicas da sífilis na cavidade oral: uma revisão bibliográfica

Ana Beatriz Villar Medeiros[1], Renivânia Pereira da Silva[2], Francimária Aparecida da Silva Oliveira[3], Letícia Amanda Fontes de Morais[4], Custódio Leopoldino de Brito Guerra Neto[4], Ângelo Roncalli Oliveira Guerra[5], Andryele Eduarda de Araújo Medeiros[6], Maria Heloyze Medeiros de Araújo[5], Larissa de Alcântara Pereira[2]

ABSTRACT

Introduction: Syphilis is a sexually transmitted infection caused by *Treponema pallidum* bacterium, which impact on a significant increase in contagions reported worldwide, bringing up the need of urgent actions to ensure the control, treatment, and diagnosis of the disease. **Objective:** Given this context, this work presents a bibliographical review on syphilis, aiming to describe the most common oral manifestations that occur on the four stages of this infection. **Methods:** For the literature review, the searches were carried out in the PubMed, Science Direct, Scientific Electronic Library Online, Latin American and Caribbean Health Sciences Literature and databases of Virtual Health Library. **Results:** Regarding the primary syphilis, the main clinical manifestations in the oral cavity include chancres in the palate, buccal mucosa, tongue, and lips. In the secondary stage, the presence of diffuse and nonspecific oral lesions was identified. In tertiary syphilis, stomatitis and glossitis are present, being the hard palate and the tongue the main affected regions. In congenital syphilis, the patients are affected with dental and jaw malformations. **Conclusion:** The clinical manifestations of syphilis in the oral cavity can appear at any stage of the infection, being the oral cavity the second most affected region by this sexually transmitted infection. Therefore, the knowledge regarding this subject is extremely important for health professionals, as well as for the population, being essential to carry out the correct diagnosis and adequate treatment for the rapid cure of this infection.

Keywords: Syphilis. Sexually transmitted diseases. Public health.

RESUMO

Introdução: A sífilis é uma infecção sexualmente transmissível oriunda da bactéria *Treponema Pallidum,* com transmissão através de relações sexuais sem o uso de preservativos ou por contato com lesões contaminadas. Nos últimos anos, diversos novos casos estão sendo reportados de forma alarmante, mostrando uma realidade dura sobre as dificuldades do diagnóstico da doença. **Objetivo:** Diante desse contexto, este trabalho apresenta uma revisão bibliográfica sobre a sífilis, com o objetivo de descrever as manifestações orais mais comuns nos quatros estágios possíveis da doença. **Métodos:** Para a revisão de literatura, realizou-se a busca dos artigos nas bases de pesquisas PubMed, Science Direct, Scientific Electronic Library Online, Literatura Latino-Americana e do Caribe em Ciências da Saúde e Biblioteca Virtual em Saúde. **Resultados:** Observou-se que, na sífilis primária, as principais manifestações clínicas na cavidade oral ocorrem com a presença de cancros no palato, na mucosa jugal, na língua e nos lábios. No estágio secundário, identificou-se a presença de lesões orais difusas e inespecíficas. Na sífilis terciária, podem ocorrer estomatites e glossites, sendo o palato duro e a língua as principais regiões acometidas. Na sífilis congênita, os possíveis sinais clínicos na cavidade oral são malformações dentárias e nos maxilares. **Conclusões:** As manifestações clínicas da sífilis na cavidade oral podem surgir em qualquer estágio da infecção, sendo a cavidade oral a segunda região com maior acometimento da infecção. Portanto, é de extrema importância o conhecimento das manifestações orais da sífilis pelos profissionais da área da saúde, bem como pela população, sendo fundamental o correto diagnóstico e tratamento rápido para a cura precoce da doença.

Palavras-chave: Sífilis. Infecções sexualmente transmissíveis. Saúde pública.

[1]Universidade Federal do Rio Grande do Norte, Center of Health Sciences, Department of Dentistry – Natal (RN), Brazil. E-mail: ana.beatriz.villar.066@ufrn.edu.br
[2]Universidade Federal do Rio Grande do Norte, School of Science and Technology – Natal (RN), Brazil. E-mails: renivania.pereira.104@ufrn.edu.br; larissadealcantara@outlook.com.br
[3]Universidade Federal do Rio Grande do Norte, Center of Technology, Department of Biomedical Engineering – Natal (RN), Brazil. E-mail: francimaria.oliveira.101@ufrn.edu.br
[4]Universidade Federal do Rio Grande do Norte, Center of Health, Postgraduate Program Professional Master's Degree in Health Management and Innovation – Natal (RN), Brazil. E-mails: leticia.fontes@live.com; custodio.guerra@ufrn.br
[5]Universidade Federal do Rio Grande do Norte, Center of Technology, Department of Biomedical Engineering – Natal (RN), Brazil. E-mails: angelo.roncalli@ufrn.br; maria.araujo.703@ufrn.edu.br
[6]Universidade Federal do Rio Grande do Norte, Center of Technology, Department of Mechanical Engineering – Natal (RN), Brazil. E-mail: andryele.medeiros.089@ufrn.edu.br

INTRODUCTION

Syphilis is a chronic sexually transmitted infection (STI) which affects society since the 15th century. Its etiologic agent is the*Treponema pallidum* bacterium, a gram-negative bacterium with a helical structure that has high transmission power in different ways. The most common way syphilis is spread is through sexual contact with an infected person's sore or through any contaminated lesions, characterizing acquired syphilis. This infection is also disseminated through vertical transmission, when the infected pregnant woman transmits the infection to the fetus, called congenital syphilis.

The course of syphilis infection includes four clinical stages — primary, secondary, latent, and tertiary syphilis —, which are intercalated by latency moments, when the disease becomes asymptomatic[(1)]. At the primary stage, the infection manifests itself in any part of the body's mucosal surface, including chancres in the buccal mucosa (painless sores). The secondary stage starts between

the fourth and eighth week with clinical manifestations in the oral mucosa. Although it is possible detect syphilis oral manifestations at first stage, the infection signs are often diagnosed at secondary stage of the disease, with whitish mucous plaques that have high infectivity, with whitish edges distributed in the oral mucosa and oropharynx, mainly in the tongue, lips, and buccal mucosa[2].

Between the primary and secondary stages, there is a latency moment, which is an asymptomatic stage that has no clinical signs and no noticeable symptoms. This stage can also be divided into the recent latent stage (up to one year of infection), and late latent stage, when the infection persists for more than one year. The time duration of latent syphilis is inconstant and may be interrupted by the signs and symptoms of the secondary or tertiary syphilis[3].

The tertiary syphilis — which happens after a latency moment and can last between 1 and 30 years — is the most critical syphilis stage, triggering cardiovascular and neurological disorders, which can lead to death[4]. At this stage, there is granulomatous inflammation and diffuse interstitial glossitis into the oral cavity mucosa, resulting in a scenario that contributes to the presence of leukoplakias and carcinomas[5].

In this context, the syphilis diagnosis is still a hard process, considering the lesions' aspects that may resemble other pathological characteristics which require greater attention from physicians, dentists, and pathologists[6]. In order to define the diagnosis of syphilis, it is necessary to correlate clinical data, the results of diagnostic tests, the previous transmissions information from patient, and the investigation about a possible current infection exposure[7], being also important to combine the anamnesis with the treponemal and nontreponemal tests.

To confirm the diagnosis, it is possible to do the rapid test (treponemal test), which is available at the Sistema Único de Saúde (SUS) health services, being practical and easy to handle for health professionals, taking up to 30 minutes for the exam result, not being necessary a complex laboratory. Currently, this is the main way to diagnose acquired syphilis in Brazil. In cases that patient exams result positive for syphilis according to the rapid test, a blood sample should be asked, which should be sent to a laboratory test (to undergo a non-treponemal) to confirm the syphilis diagnosis[7].

Regarding the congenital syphilis diagnosis, the children's mother should be evaluated according to their previous clinical and epidemiological information. Concomitantly, the children should be evaluated through physical examination and also by analyzing children's syphilis exam, which should be done at the slightest possibility of the disease, including radiological and laboratory tests, to conclude a precise and correct diagnosis for congenital syphilis. After all this process, adequate treatment should be performed[7].

The first attempts on syphilis treatment were performed by using iodides, mercury, arsenic, bismuth, and even increased body temperature, based on the low resistance of the bacteria to high temperatures, however, these methods were not successful, as they were not efficient[8,9]. Nevertheless, in 1928, penicillin was discovered and stood out as an effective medicine for the treatment of syphilis, acting by interfering with the synthesis of the *Treponema pallidum* cell wall, being useful in all stages of syphilis and playing an important role in the cure of this infection. In this perspective, due to the drug's efficiency, the penicillin treatment caused a false sense of control in the population; for that reason, contamination has increased in alarming numbers, showing that the society should be more conscious about this disease[10,11].

Even today, benzathine penicillin is the most common choice for syphilis treatment, which is a drug from the class of antibiotics, bactericidal and with slow absorption. The treatment protocol must be adapted according to the stage of the disease, as different and progressive doses are required according to the disease evolution. After completing the treatment, it is essential to do a follow-up with the patient, by collecting non-treponemal tests to guarantee the cure. It is important highlight that all the sexual partners that the infected person had in the last 3 months must be tested and treated to break the transmission cycle[7,10,11].

Although there are accessible and effective resources for syphilis treatment, this infection has again gained prominence in recent years as a serious public health problem, due to the considerable increase of new cases in the world. In addition, it was also observed that, in Brazil, there was an increase in reports on syphilis cases regarding pregnant women, acquired and congenital syphilis[11], bringing up the need to control and develop strategies to combat this STI.

OBJECTIVE

Given the context, this work aims to carry out a bibliographical review to provide information regarding the main clinical manifestations of syphilis in the oral cavity, in order to help the analysis of health professionals during the construction of knowledge concerning this subject, once the oral cavity represents one of the most common areas for syphilis lesions.

METHODS

Regarding the review on the main syphilis manifestations in the oral cavity, it was carried out through the study of papers with subjects inherent to this work that were themselves available in the main scientific research databases.

Initially, keywords were defined in English, Portuguese, and Spanish, according to the platform for descriptors Descritores em Ciência da Saúde/Medical Subject Headings (DeCS/MeSH), as shown in **Table 1**. For this stage, it was necessary to use boolean "AND" and "OR" to build keywords research terms.

Thereafter, the search was carried out in PubMed, Scientific Electronic Library Online (SciELO), Latin American Literature in Health Sciences (LILACS) and Virtual Health Library (VHL)

Table 1. The keyword terms to research papers in the scientific databases.

Language	Research terms
EN	("sífilis" AND "manifestation" AND "oral") ("sífilis" AND "oral") ("sífilis" AND "mouth")
PT	("sífilis" AND "manifestação" AND "oral") ("sífilis" AND "oral") ("sífilis" AND "bucal")
ES	("sífilis" AND "bucal")

EN: English; PT: Portuguese; ES: Spanish.
Source: Prepared by the authors (2022).

databases, all accessed through the Periódicos Capes platform, via the Integrated System of Academic Activities Management that belongs to the Federal University of Rio Grande do Norte. Papers were filtered between 2012 and 2022; in addition were included those relevant materials (papers, report, book), even though they were from previous years.

The criteria to include any paper in this study were:

1. papers that the subject was on syphilis in the oral cavity;
2. papers completely included in the scientific databases: PubMed, Science Direct, SciELO, LILACS and VHL;
3. papers published in Portuguese, Spanish and English; and
4. papers with a publication in the last 5 years, except for the important books and national health reports.

The exclusion criteria were:

1. duplicate papers;
2. papers that did not address the main subject of this work; and
3. papers without the full text available on the scientific database.

Figure 1 shows the flowchart of the process of searching and sorting the articles found in the scientific databases.

The peer review took place based on information from the titles and papers' abstracts, considering those that were consistent with the subject of this work. Then, the full article was evaluated and a last selection was carried out, according to the criteria previously mentioned.

To organize the papers, a standardized spreadsheet was used to select the following data: author(s), year of publication, keywords/descriptors, abstract, results, and conclusion.

RESULTS

After the research on the scientific databases, 15 papers fulfilled all criteria to compose the results of this work. **Table 2** presents information regarding the authors, years of publication and titles concerning the papers that were selected.

It was observed that, among the 15 papers, 11 highlight the increase in cases of syphilis in Brazil in the last five years, warning about

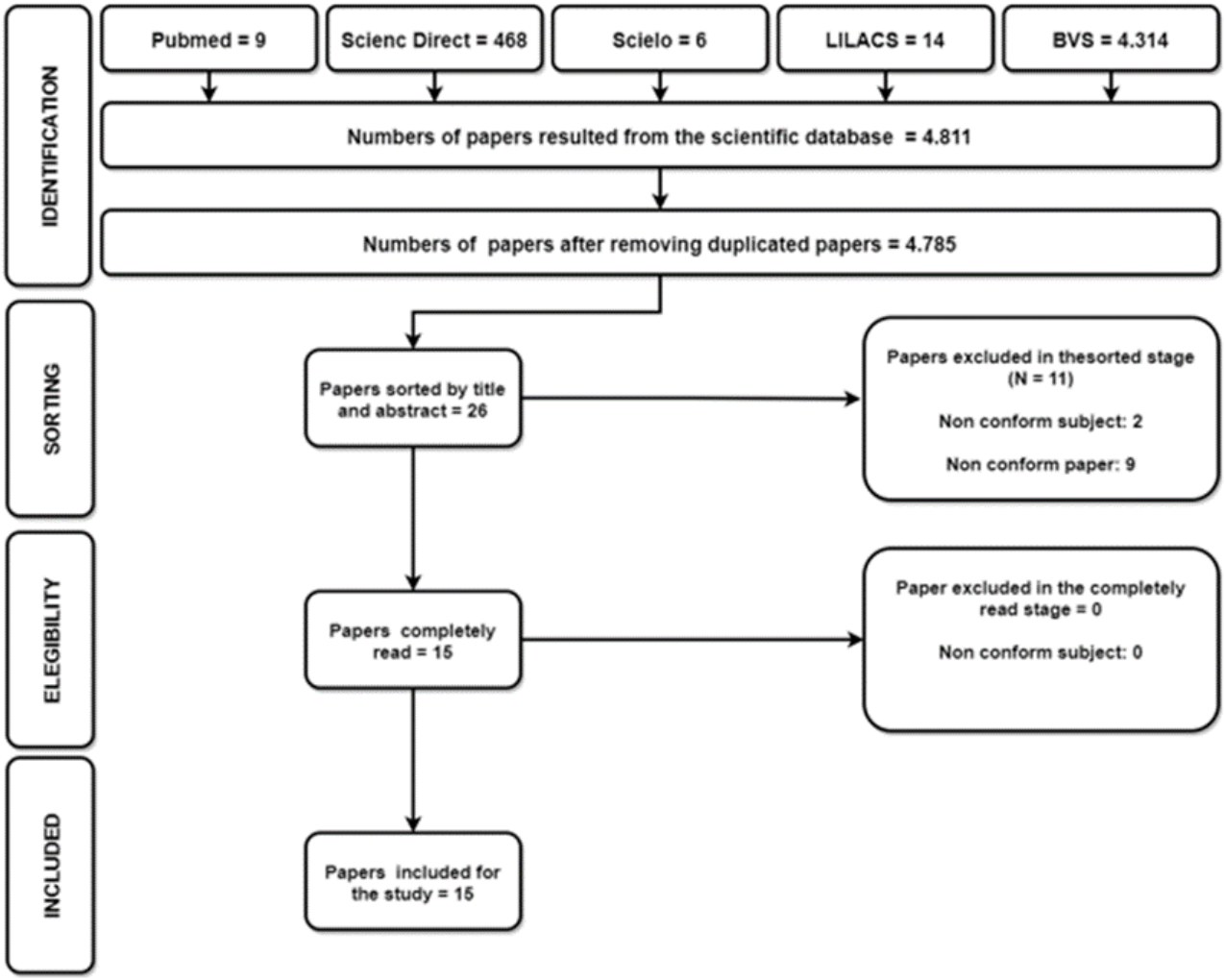

Source: Prepared by the authors (2022).

Figure 1. Flowchart regarding the selection of the papers for this review.

Table 2. Information regarding the authors, years of publication and titles concerning the papers that were selected for the review.

Authors (publication years)	Titles
Seibt et al.[2]	Secondary syphilis in the oral cavity and the role of the dental surgeon in STD prevention, diagnosis and treatment: a case series study
Souza[18]	Manifestações clínicas orais da sífilis
Kojima et al.[12]	An update on the global epidemiology of syphilis
Paiva et al.[13]	Exclusively oral manifestation of secondary syphilis
Silva et al.[14]	Recent syphilis with oral manifestation: three case reports treated at a STD clinic
Santos et al.[15]	Manifestações orais da sífilis: revisão sistematizada de literatura
Wang et al.[16]	A new specimen for syphilis diagnosis: evidence by high loads of *Treponema pallidum* DNA in saliva
Batista et al.[1]	A sífilis e suas manifestações bucais: relato de casos clínicos
Matias et al.[17]	Diagnosing acquired syphilis through oral lesions: the 12 year experience of an Oral Medicine Center
Souza et al.[11]	Sífilis: uma doença sistêmica com manifestações orais
Pereira et al.[10]	Achados clínicos da repercussão oral da sífilis em região endêmica no nordeste do Brasil
Soerger et al.[4]	Manifestação primária de sífilis em cavidade oral
Farmkiss et al.[20]	Condylomata lata of the oral commissure: an unexpected presentation of secondary syphilis
Binda et al.[19]	Manifestações orais da Sífilis: uma revisão da literatura

Source: Prepared by the authors (2022).

the importance of preventing this disease by bringing knowledge to society and promoting actions to guarantee the improvement of the surveillance system in health[1,2,4,10-17].

Regarding the clinical manifestations caused by syphilis, Santos et al.[15] and Silva et al.[14] point out that the oral cavity is one of the most affected areas, second only to the genital regions. This information is also corroborated by De Paiva *et al*.[13] and De Souza[18], which also clarify that lesions in the oral cavity can appear at any stage of the infection, with predominance in the secondary phase of syphilis.

According to the literature, the diagnosis of primary syphilis has sometimes been made based on the local lesion characteristics, considering that the initial lesions occur at the local where *Treponema pallidum* has penetrated. In this perspective, Seibt *et al*.[2] and Soerger et al.[4] inform that, in the exact place where this microorganism has penetrated, there is formation of hard chancre and, associated with this, systematically, a possible reactive lymphadenomegaly. Santos *et al*.[15], Souza[18] and Souza *et al*.[11] corroborate this information by saying that, in this stage, there are oral manifestations which shows chancre, becoming visible for a certain period of time, develops as a nonspecific hardened papular lesion and evolves as a painless central ulcer with well-defined margins, characterized by a wet and clean base. In that regard, Seibt *et al*.[2] and Soerger *et al*.[4] point out that the infection mainly affects the tongue, soft palate, hard palate, lips, labial commissures, and buccal mucosa.

Still about the primary phase of syphilis, when the lesion occurs in the most superficial layers of the mucosa, Pereira *et al*.[10], Batista *et al*.[1], Matias *et al*.[17] and De Souza *et al*.[11] add that the presence of chancre can cause swelling of adjacent tissues, which can lead to asymmetry and local discomfort. In addition, depending on the location, these lesions can ulcerate, form pseudomembranes, detachable plaques and even exudation, due to local inflammation, associated with painful symptoms and infarcted submandibular and cervical lymph nodes[1,2,4,10-18]. Additionally, Binda *et al*.[19] bring to light that, when the lesion is not treated, the infectious microorganism spreads, the lesion regresses and, thus, initiates secondary syphilis.

In the secondary stage, syphilis presents itself clinically with ulcerative heterogeneous oral lesions, with possible onset of syphilitic mucositis, usually manifested on the tongue, buccal mucosa, and palate, followed by the oropharynx, as well as the presence of symptoms such as burning in the oral cavity and xerostomia[2,4,11,13-15,18]. In this scope, Binda *et al*.[19] reinforce that the most common lesions involve redness or the appearance of whitish spots, which may result in pain and discomfort at the affected site. Clinical manifestations of secondary syphilis may include traumatic ulcers, herpetic infections, tuberculosis, lichen planus, erythema multiforme, and squamous cell carcinoma[1,2,4,10-18]. **Figures 2 and 3** show the visible manifestations referring to the primary and secondary syphilis in the oral cavity.

Farmkiss *et al*.[20] evaluate that, systemically, with the occurrence of the microorganism in the lymphatic vessels, the signs and symptoms of syphilis are presented in different ways, such as sore throat, malaise, fever, and weight loss. The most prevalent sign for diagnosing this disease stage is the presence of a painless rash in the palmoplantar region[19].

Tertiary syphilis is the most severe stage and occurs from one to 30 years after the initial infection in patients who have not received treatment in the primary and secondary stages[19]. Therefore, this phase is characterized as the most critical moment of the infection, which can lead the infected person to death.

At this stage, in the oral region, granulomatous inflammation (gum) and glossitis may be present, with the hard palate and tongue being the main affected regions — and may also affect the soft palate and buccal mucosa, Seibt *et al*.[2], Paiva et al.[13] and Santos *et al*.[15] agree, when stating that granulomatous inflammation can cause severe tissue destruction, reaching regions beyond the mucosa, such as bones and internal organs (**Figure 4A**). On the palate, in general, gums can compromise the region, causing large, ulcerated lesions to reach the nasal cavity, which can lead to intense tissue destruction. In this sense, the location of these lesions can interfere with the treatment and prognosis of the disease, since, when they affect the hard palate, they can cause perforation and oroantral communication, as shown in **Figure 4B**. When the tongue is involved, it can form a lobulated, irregular, and diffuse pattern, called interstitial glossitis, which results in reduced tongue musculature, diffuse atrophy, and absence of tongue dorsum papillae[2,11,15,18,19].

To evaluate the congenital syphilis, which is caused by vertical transmission, it is considered the triad of pathognomonic signs, used since the 19th century. The clinical signs manifested are Hutchinson teeth, interstitial ocular keratitis, deafness (associated with the eighth pair of cranial nerves), frontal bossing, atretic maxilla and high palate. Certain clinical signs of congenital syphilis may appear weeks after the child's birth, with emphasis on the need for clinical follow-up for suspected cases, as these symptoms can cause deficits in the child's development[11,13,15]. **Figure 5** shows clinical aspects of congenital syphilis such as the dental defect called Hutchinson's incisors and mulberry molars that have an irregular occlusal anatomy.

Thus, if any of these symptoms are absent, it is necessary to correlate clinical information and observations of other clinical signs. That said, Bind *et al.*[19] bring up that untreated children who survived evolve to latent syphilis and, later, to tertiary syphilis, suffer damage to bones, teeth, eyes, ears and brain. **Table 3** shows a resume of the main oral alterations aggravated to syphilis, according to the infection stage and the most common locations of lesions.

In order to define syphilis diagnosis, it is necessary to correlate clinical data, the results of diagnostic tests, the history of past infections and the investigation of recent infection exposure [7], making it essential to carry out direct tests for the detection of *Treponema pallidum*, for example by obtaining samples collected directly from primary or secondary lesions in adults or children.

Treponemal tests are the first to show positive results after infection. Although the time for the emergence of treponemal antibodies may vary from individual to individual, in most cases they can be detected ten days after the appearance of the primary syphilis lesion (hard chancre).

Non-treponemal tests (Venereal Disease Research Laboratory — VDRL —, Rapid Plasma Regain — RPR — or Toluidine Red Unheated Serum Test — TRUST), in turn, detect anticardiolipin antibodies, which are not specific for *Treponema pallidum* G antigens. They can be quantitative or qualitative. Quantitative tests allow antibody titration. The result must be expressed in titles, being important for the diagnosis and monitoring of response to treatment[21]. The qualitative non-treponemal test indicates the presence or absence of antibody in the tested sample.

In non-treponemal tests, especially in secondary syphilis, when antibodies are produced in large numbers, false-negative results may occur due to the prozone phenomenon. The prozone phenomenon does not occur in treponemal tests[7].

For the diagnosis of syphilis, it is recommended to use only the treponemal test that detects total antibodies (IgG and IgM), since, unlike other diseases such as toxoplasmosis, tests that detect IgM antibodies alone are not useful as indicators of recent infection. Treponemal tests are the first to show positive results after infection[7]. In approximately 85% of cases, treponemal tests remain reactive throughout life in people who were infected with syphilis, regardless of treatment (serologic scarring), thus, they are not useful for monitoring therapy response[21].

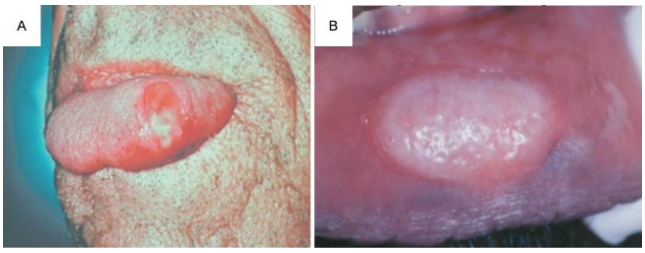

Source: Souza et al.[11].

Figure 2. Clinical aspect of primary syphilis lesion on the edge of the tongue (A) and labial mucosa (B).

Source: Souza et al.[18].

Figure 3. Clinical aspect of secondary syphilis lesions on the inferior lip (A), on the edge of the tongue (B), on the tongue (C) and on the oral mucosa (D).

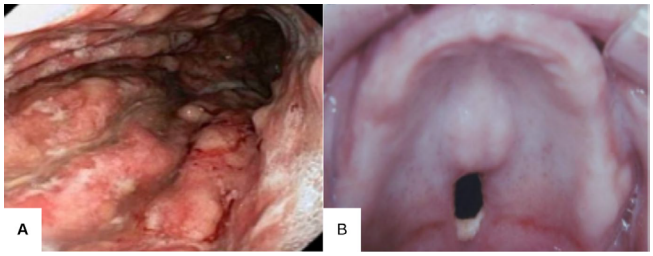

Source: Souza et al.[11] and Neville et al.[23].

Figure 4. Clinical aspects of tertiary syphilis, gastric syphilis (A) and palate perforation (B).

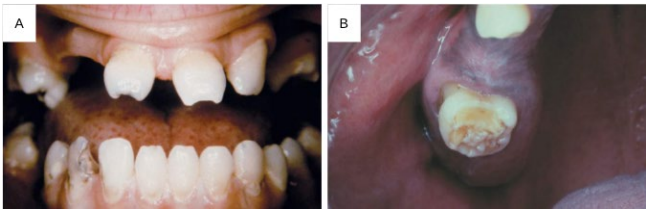

Source: Neville et al.[23]

Figure 5. Clinical aspects of tertiary syphilis, Hutchinson's incisors (A) and mulberry molar (B).

Table 3. Resume of the main oral alterations according to the stage of infection and the respective sites of the lesions.

Syphilis stage	Oral clinical manifestations	Affected site
Primary syphilis	Painless ulceration, unique, nonspecific; vascular proliferation.	Tongue, hard palate, soft palate, lip, jugal mucosa.
Secondary syphilis	Ulcerative maculopapular oral lesions; whitish or reddish mucus plaques.	Tongue jugal mucosa, hard palate, soft palate.
Tertiary syphilis	Granulomatous inflammation (gum), luetic glossitis, interstitial glossitis.	Palate, tongue.
Congenital syphilis	Arched palate, atrophic glossitis, Hutchinson's incisors, blackberry molars, granulomatous inflammations (gums).	Teeth, palate, tongue.

Source: Adapted from Santos et al.[15].

In this context, aiming for the full treatment, it must be done correctly by doing the laboratory tests. Thus, the treatment is carried out in a standard and consolidated way with benzathine penicillin, a bactericidal antibiotic, available in the public health network.

When there is no treatment in primary and secondary syphilis, the signs and symptoms of the infection will disappear, which will enter a latency phase, considered recent in the first year and late thereafter[3].

The penicillin dose that should be used will depend on the clinical syphilis stage, which may be 2.4 million IU, in a single intramuscular dose, for primary, secondary and recent latent syphilis (with infection up to one year), or a dose of 2.4 million IU, in 3 doses intramuscularly, with a week interval between each one, for those with syphilis infection for more than one year, in the latent stage or in tertiary syphilis[21].

As an alternative treatment for patients with syphilis who are allergic to or have an adverse reaction to benzathine penicillin, another antibiotic should be used, such as doxycycline 100 mg, orally, twice a day, for a period of 15 days (except for pregnant women), for primary, secondary, or recent latent syphilis. And doxycycline 100 mg, orally, twice a day, for 30 days (except for pregnant women), is also used for the treatment of syphilis with more than one year of infection, in the latent stage or in tertiary syphilis[10,11,21].

For the treatment of syphilis in pregnant women, benzathine penicillin is applied in the standard dose according to the stage of the disease. This is the only medicine capable of preventing vertical transmission (syphilis transmitted from the mother to the fetus) [7]. In case of adverse reaction to this drug, it is used ceftriaxone 1g, intravenously or intramuscularly, once a day, for 8 days for pregnant women, for primary, secondary, or recent latent syphilis. Thus, for latent syphilis and tertiary syphilis, ceftriaxone 1g is used, intravenously or intramuscularly, once a day, for a period of 10 days[10,11,21].

Furthermore, when treated and cured syphilis does not confer immunity, therefore, a person can be reinfected as many times as they are exposed to *Treponema pallidum*[7]. In this context, emphasis is placed on preventing action to the other partner who is not infected, with both sexual partners having to be tested and treated for syphilis in case of a positive result for the infection because, as highlighted by Scherer *et al*.[22], this action can also prevent the vertical transmission of sexually transmitted infections in cases of pregnant women, being of paramount importance for the safety of fetuses.

DISCUSSION

To guarantee a good prognosis for infected patients, taking in account that the lesions caused by the *Treponema pallidum* are easily visualized and monitored by health professionals, it is essential to make a precise diagnosis on oral cavity to detect any manifestation of this infection[2,4,11,13,15,18].

In view of this information, it is necessary that nonspecific lesions be investigated and closely monitored, considering that, if they are consequences of syphilis contamination, they will disappear naturally and affected patients may evolve the infectious condition to the latent stage of the disease, without visible symptoms. In this aspect, De Paiva *et al*.[13] agree with this information stating that about 30% of patients evolve to this clinical condition.

In this perspective, the dental surgeon plays an important role in the diagnosis of syphilis lesions present in the oral cavity, and can act in requesting the laboratory tests, such as the VDRL, as well as asking to serology tests for other sexually transmitted diseases. Thus, oral health professionals must be aware and adequately trained so that they develop a high level of clinical analysis in the diagnosis of syphilis, with anamnesis being the first step to reach the correct diagnosis, a fact also corroborated by Pereira *et al*.[10].

Given this context, the treatment of syphilis should be carried out as soon as possible after diagnosis, for the benefit of the patient, who will be cured of the disease, as well as to cut transmission from person to person. Consequently, whenever possible, it is very important that, after any non-treponemal qualitative test showing a reactive result, the quantitative test is also performed in sequence[7].

Moreover, it is emphasized that this infection is a worrying public health problem and must be resolved urgently, given the possible negative consequences to the population. As does the "Sífilis Não" project, from the Laboratory of Innovation and Technology in Health (LAIS/HUOL), a national reference in actions, projects, and research for syphilis and another STI. The project offers knowledge to the population, encouraging them to seek health services in cases of suspicious injuries and, thus, the project encourages efforts to combat this STI.

Strengths

The strengths of this work are the findings through a solid bibliographical search, in several current papers on the main scientific databases, which approach the aspects and clinical sites most relevant to the appearance of syphilis oral manifestations. In addition, in an objective way, this study also provides a wealth of details concerning the knowledge about the clinical characteristics of syphilis in the oral cavity. This is significant because it is a helpful tool to guide professionals, students, and researchers from the health field by promoting approachable studies on this subject.

Limitation

As limiting factors for this study, it is pointed to the low number of current publications focused exclusively on the syphilis oral manifestations subject and also it is mentioned the absence of

standardized and specific clinical studies for this STI. Furthermore, it is also worth mentioning the lack of studies on syphilis in the oral cavity, analyzing the long-term effects of manifestations in the mouth and their complications for patients.

CONCLUSION

Based on the bibliographic review, it is concluded that the clinical manifestations of syphilis in the oral cavity can appear at any stage of the infection, but there is a predominance to appear in the secondary phase of syphilis, with the oral cavity being the second region most affected by this infection.

There are characteristic clinical signs of each stage of syphilis in the oral cavity — with the presence of chancres, ulcers, mucous plaques, granulomatous inflammation, Hutchinson's incisors, mulberry molars, among others —, as well as there are parts oral cavity that are more propitious to be infected by syphilis, such as lips, tongue, soft palate, hard palate, labial commissures, buccal mucosa, and teeth.

Thus, it is also concluded that syphilis should be considered as a diagnostic hypothesis to be investigated in patients with oral lesions, especially if it presents similar characteristics to the clinical manifestations of syphilis. In case of suspicion, it is the dentist's responsibility to request a serological test or a biopsy and they may also ask for a quick test in public health units. The dental surgeon has a fundamental role in the diagnosis of this disease, due to the visible signs that often appear in the oral manifestations for syphilis. Added to this, the evaluation of the oral cavity becomes important for cases in which patients who are possibly infected by syphilis also have genital lesions.

Therefore, the knowledge concerning the oral manifestations of syphilis by health professionals is extremely important, being essential to the correct diagnosis and, mainly, the precise treatment for the rapid cure of the disease. In this sense, studies on the subject should be encouraged for an improvement in learning on syphilis.

Approval by the Human Research Ethics Committee

The current study is based on a bibliographic review, in which it was searched for papers from scientific databases. Therefore, no research protocol in human beings was submitted to the appreciation of the ethics committee.

Participation of each author

ABVM: Conceptualization, Data curation, Formal analysis, Methodology, Visualization, Writing – original draft, Writing – review & editing. RPS: Conceptualization, Data curation, Formal analysis, Investigation, Methodology, Visualization, Writing – original draft, Writing – review & editing. NVRV: Conceptualization, Data curation, Formal analysis, Investigation, Methodology, Visualization, Writing – original draft, Writing – review & editing. LAFM: Conceptualization, Data curation, Formal analysis, Methodology, Visualization, Investigation, Visualization, Writing – original draft, Writing – review & editing. CLBGN: Formal analysis, Project administration, Supervision, Validation, Writing – review & editing. AROG: Formal analysis, Project administration, Supervision, Validation, Writing – review & editing. AEAM: Conceptualization, Data curation, Formal analysis, Investigation, Methodology, Visualization, Writing – original draft, Writing – review & editing. MHMA: Formal analysis, Methodology, Visualization, Writing – review & editing. LAP: Formal analysis, Methodology, Visualization, Writing – review & editing.

Funding or other financing

The authors declare no financial support.

Conflict of interest

The authors declare no conflicts of interest.

REFERENCES

1. Batista LCSA, Santos LO, Terêncio MCO, Silva NVRV, Raimundo RC, Silveira MMF, et al. A sífilis e suas manifestações bucais: relato de caso clínico. REAOdonto. 2020;1:e 3446. https://doi.org/10.25248/reaodonto.e3446.2020
2. Seibt CE, Munerato MC. Secondary syphilis in the oral cavity and the role of the dental surgeon in STD prevention, diagnosis and treatment: a case series study. Braz J Infect Dis. 2016;20(4):393-8. https://doi.org/10.1016/j.bjid.2016.03.008
3. Ministério da Saúde (BR). Manual técnico para o diagnóstico da sífilis. Brasília (DF); 2020 [cited on Fev 23, 2023]. Available from: https://www.gov.br/aids/pt-br/centrais-de-conteudo/publicacoes/2021/manual-tecnico-para-o-diagnostico-da-sifilis
4. Soerger P, Dias PHFS, Cruz EZ, Lima SRR, Santos FP, Rosa ACG. Manifestação primária de sífilis em cavidade oral. revista de patologia do Tocantins. 2021;8(2):7-11. http://doi.org/10.5335/rfo.v22i1.6981
5. Teixeira FM. Sífilis: manifestações orais [dissertação]. Porto: Universidade Fernando Pessoa, 2018.
6. Schuch LF, Silva KD, Arruda JAA, Etges A, Gomes APN, Mesquita RA, et al Forty cases of acquired oral syphilis and a review of the literature. Int J Oral Maxillofac Surg. 2019;48(5):635-43. http://doi.org/10.1016/j.ijom.2018.10.023
7. Ministério da Saúde (BR). Boletim epidemiológico de sífilis número especial. Brasília (DF); 2021 [cited on Fev 23, 2023]. Available from: https://www.gov.br/saude/pt-br/centrais-de-conteudo/publicacoes/boletins/epidemiologicos/especiais/2021/boletim_sifilis-2021_internet.pdf
8. Avelleira JCR, Bottino G. Sífilis: diagnóstico, tratamento e controle. An Bras Dermatol. 2006;81(2):111-26. https://doi.org/10.1590/S0365-05962006000200002
9. Vázquez GGH. Vênus nos braços de mercúrio, bismuto e arsênio Notas históricas sobre sífilis gestacional antes da penicilina. Sex Salud Soc (Rio J.). 2018;28:226-45. https://doi.org/10.1590/1984-6487.sess.2018.28.12.a
10. Pereira RPS, Medeiros Junior MD, Pereira MO, França LC, Ramos LVS, Lima CA, et al. Achados clínicos da repercussão oral da sífilis em região endêmica no nordeste do Brasil. Braz J Develop. 2021;7(3):32608-23. https://doi.org/10.34117/bjdv7n3-807
11. Souza TS, Polignano GAC. Sífilis: uma doença sistêmica com manifestações orais. Cad Odontol Unifeso. 2020;2(1):14-23.
12. Kojima N, Klausner JD. An update on the global epidemiology of syphilis. Curr Epidemiol Rep. 2018;5(1):24-38. https://doi.org/10.1007/s40471-018-0138-z
13. Paiva JPG, Calone IS, Medeiros NE. Exclusively oral manifestation of secondary syphilis. Repositório. DST - J Bras Doenças Sex Transm. 2018;30(3):107-10. https://doi.org/10.5533/DST-2177-8264-201830306
14. Silva SD, Barros GIS, Silva AMP, Gouvêa TVD, Pinho CRP, Canabarro A, et al. Recent syphilis with oral manifestation: three case reports treated at a STD clinic. DST - J bras Doenças Sex Transm. 2018;30(4):137-41. https://doi.org/10.5533/DST-2177-8264-201830406

15. Santos ES, Sá JO, Lamarck R. Manifestações orais da sífilis: revisão sistematizada de literatura. Arch Health Invest. 2019;8(8):413-6. https://doi.org/10.21270/archi.v8i8.3330
16. Wang C, Hu Z, Zheng X, Ye M, Liao C, Shang M, et al. A new specimen for syphilis diagnosis: evidence by high loads of *Treponema pallidum* DNA in saliva. Clin Infect Dis. 2021;73(9):e3250-8. https://doi.org/10.1093/cid/ciaa1613
17. Matias MDP, Jesus AO, Resende RG, Caldeira PC, Aguiar MCF. Diagnosing acquired syphilis through oral lesions: the 12 year experience of an Oral Medicine Center. Braz J Otorhinolaryngol. 2020;86(3):358-63. https://doi.org/10.1016/j.bjorl.2018.12.010
18. Souza BC. Manifestações clínicas orais da sífilis. RFO. 2017;22(1):82-5. http://doi.org/10.5335/rfo.v22i1.6981
19. Binda ALC, Sá ACSF, Franco AG, Borba TOS, Souza HYMS, Silva JWL, et al. Manifestações orais da sífilis: uma revisão da literatura. Res Soc Dev. 2021;10(12):e585101220943. http://doi.org/10.33448/rsd-v10i12.20943
20. Farmkiss L, Shadrick V, Bracey T. Condylomata lata of the oral commissure: an unexpected presentation of secondary syphilis. Diagn Histopathol.2021;27(5):226-9. https://doi.org/10.1016/j.mpdhp.2021.02.007
21. Ministério da Saúde (BR). Protocolo Clínico e Diretrizes Terapêuticas para Atenção Integral às Pessoas com Infecções Sexualmente Transmissíveis. Brasília (DF); 2015 [cited on Jan 1, 2023]. Available from: https://bvsms.saude.gov.br/bvs/publicacoes/protocolo_clinico_diretrizes_terapeutica_atencao_integral_pessoas_infeccoes_sexualmente_transmissiveis.pdf. Acesso em 30 de janeiro de 2023.
22. Scherer A, Silveira MF, Nunes BP. HIV, Hepatitis B, Hepatitis C, and Syphilis: prevalence and serodiscordance between women and their partners. DST [Internet]. 2022 [cited on Jan 30, 2023]. Available from: https://www.bjstd.org/revista/article/view/1194
23. Neviller BW, Damm DD, Allen CM, Bouquot JE. Patologia oral e maxilofacial. Trad. 4th ed. Rio de Janeiro: Elsevier; 2016.

Address for correspondence
ANA BEATRIZ VILLAR MEDEIROS
Av. Sen. Salgado Filho, 1787 – Lagoa Nova
Natal (RN), Brazil.
CEP: 59056-000
E mail: ana.beatriz.villar.066@ufrn.edu.br

Received on: 12.16.2022
Approved on: 02.07.2023

This is an open access article distributed under the terms of the Creative Commons license.