Lesions suspected of gastric syphilis: case report with complete remission after treatment with benzathine penicillin

Lesões suspeitas de sífilis gástrica: relato de caso com remissão completa após tratamento com penicilina benzatina

Arthur Xavier Raphael[1], Marco Aurélio dos Santos Silva[1], Robisney Avelar[2], Nilcimar Lourenço Miranda[3], Alexandre Braga Raphael[4], Paulo Roberto Rodrigues da Cunha[5], Angeli Braga Raphael Maniero[6], Leonardo Barbosa da Cunha[7,8], Pedro Henrique Xavier Raphael[9]

ABSTRACT

Introduction: Syphilis is a sexually transmitted disease identified as a global health problem. Its gastric, esophageal and/or intestinal involvement occurs in around 1% of cases. The descriptions of endoscopic lesions and histopathological biopsies are similar to other more prevalent diseases, such as mucosal infiltrative tumors, lymphomas related to *Helicobacter pylori* infection, Crohn's disease and adenocarcinomas. **Objective:** To report the case of an adult male patient with imaging tests mimicking gastric neoplasia, which were, in fact, lesions suspected of syphilis, its resolution and management. **Case report:** A 39-year-old man sought care because of severe epigastric pain related to the postprandial period and prolonged fasting, without improvement with medication. He reported weight loss and episodes of dark-colored vomiting. On physical examination, pain on deep palpation in the epigastric region without palpable masses and peristalsis was present. An endoscopy was performed, the report of which indicated endoscopic gastritis with marked flat erosions in the antrum, with eroded, bloody, intensely friable mucosa. Also, a biopsy of the mucosa was performed, with a histopathological report resulting in a large plasma cell infiltrate, with VDRL/FTA-Abs being ordered because of the prevalence of differential diagnoses. The patient was diagnosed with syphilis and was treated with benzathine penicillin 2,400,000 IU IM in three doses, one every seven days, for a total of 7,200,000 IU. He returned in six months for reevaluation. **Conclusion:** Although this is a rare occurrence of the disease, one should always be aware of possible differential diagnoses to avoid unnecessary surgical interventions and procedures.

Keywords: Endoscopy. Histology. Syphilis. *Treponema pallidum.*

RESUMO

Introdução: A sífilis é uma doença sexualmente transmissível identificada como um problema de saúde mundial. Seu acometimento gástrico, esofágico e/ou intestinal acontece em cerca de 1% dos casos. As descrições das lesões por via endoscópica e biópsias no histopatológico se assemelham com outras doenças mais prevalentes, como, por exemplo, os tumores infiltrativos da mucosa, linfomas relacionados a infecção do *Helicobacter pylori*, doença de Chron e adenocarcinomas. **Objetivo:** Relatar o caso de um paciente masculino adulto com exames de imagem mimetizando neoplasia gástrica, sendo, na verdade, lesões suspeitas de sífilis, sua resolução e conduta. **Relato de caso:** Homem de 39 anos buscou atendimento por conta de forte epigastralgia relacionada a período pós-prandial e a jejum prolongado, sem melhora com medicação. Relatou perda ponderal e episódios de vômitos com cor escura. Ao exame físico, dor à palpação profunda em região epigástrica sem massas palpáveis e peristalse presente. Foi feita endoscopia, cujo laudo apontou gastrite endoscópica com erosões planas acentuada no antro, com mucosa erodida, cruenta, intensamente friável, e feita biópsia da mucosa, com laudo do histopatológico resultando em grande infiltrado de plasmócitos, sendo pedido VDRL/FTA-Abs por conta da prevalência de diagnósticos diferenciais. O paciente foi diagnosticado com sífilis, e foi feito tratamento com penicilina benzatina 2.400.000UI IM três doses, uma a cada sete dias, num total de 7.200.000UI, retornando em seis meses para reavaliação. **Conclusão:** Apesar de se tratar de um acometimento raro da doença, deve-se sempre estar atento aos possíveis diagnósticos diferenciais a fim de se evitar intervenções cirúrgicas e procedimentos desnecessários.

Palavras-chave: Endoscopia. Histologia. Sífilis. *Treponema Pallidum*.

INTRODUCTION

Syphilis is a sexually transmitted disease identified as a global health problem, with slow evolution, whose long-term systemic involvement, if untreated, can cause irreversible consequences[1-3].

Syphilis is caused by the bacterium *Treponema pallidum*, and gastric, esophageal and/or intestinal involvement can occur during the secondary (mainly) and tertiary phases of the disease[4], where it is considered a rare manifestation, with only around 1% of cases[5]. The symptoms, together with the findings on endoscopy, are atypical, in addition to 2/3 of the patients not showing symptoms of the disease itself. It is a mistake for clinicians to rule out this possibility for resolving the case. The low incidence and non-specific clinical features require advanced suspicion to confirm the diagnosis[5-8].

In Brazil, all notification of syphilis cases is made through the Notifiable Diseases Information System (SINAN)[1,2,9]. In the period of 2012 to June 2023, a total of 1,340,090 cases of acquired

[1]Universidade de Vassouras – Vassouras (RJ), Brazil.
E-mail: axr123a@gmail.com; marcoaurelio.ssilva@univassouras.edu.br
[2]Federação Brasileira de Gastroenterologia – Nilópolis (RJ), Brazil.
E-mail: robisney.avelar@ifrj.edu.br
[3]Laboratório Studio de Patologia – Nova Iguaçu (RJ), Brazil.
E-mail: nilcimarlourenco@gmail.com
[4]Centro Integrado de Gastroenterologia – Nova Iguaçu (RJ), Brazil.
E-mail: araphael@abrmed.com.br
[5]Universidade Nova Iguaçu, Hospital Getulio Vargas – Nova Iguaçu (RJ), Brazil. E-mail: drpaulocunha@icloud.com
[6]Sociedade de Endoscopia Digestiva – Nova Iguaçu (RJ), Brazil.
E-mail: abraphael10@gmail.com
[7]Universidade Federal do Estado do Rio de Janeiro – Nova Iguaçu (RJ), Brazil. E-mail: drleocunha@icloud.com
[8]Pontifícia Universidade Católica do Rio de Janeiro – Nova Iguaçu (RJ), Brazil. E-mail: drleocunha@icloud.com
[9]Universidade de Nova Iguaçu – Barra Mansa (RJ), Brazil.
E-mail: pedrohxr98@hotmail.com

syphilis were reported on SINAN, of which 50.0% occurred in the Southeast region. Recently, in 2022, 101,909 cases were reported in this region, representing a 47.8% increase in the disease detection rate (from 68.3 to 88.2 cases per 100,000 inhabitants)[2]. This period coincided with the COVID-19 pandemic, which made both the diagnosis and treatment of the disease difficult due to the social distancing required, impacting the relationship between patients and the Brazilian health care system[1,3,9].

The descriptions of lesions endoscopically and through biopsies in histopathology are similar to other more prevalent diseases, such as mucosal infiltrative tumors, lymphomas related to *H. pylori* infection, Crohn's disease and adenocarcinomas, among others, requiring clinical and endoscopic correlation and laboratory tests for differential diagnosis[6-8].

OBJECTIVE

To report the case of an adult male patient with suspicious lesions of syphilis in the gastrointestinal tract, to present the endoscopic and histopathological findings, to offer strategies on how to differentiate from other possible and more likely diagnoses and to describe the complete remission of clinical and serological manifestations after treatment with benzathine penicillin on an outpatient basis.

CASE REPORT

Male patient, 39 years old, white, married, businessman, resident of Nilópolis, in the state of Rio de Janeiro (Brazil), sought medical consultation at a gastroenterology clinic because of 2 months of medium to severe pain in the epigastric region. Pain was without radiation, related to the immediate postprandial period, but with reports of pain for long periods unrelated to food that did not improve with the use of proton pump inhibitors (PPI). He reported weight loss (70 to 65 kg) during the consultation period and the presence of some episodes of vomiting, with some of these episodes involving s dark-colored liquid. He was HIV negative and had intestinal regularity with normal-looking stools and normal urinary frequency.

On physical examination, he was found to be normotensive, with a heart rate of 82 beats/min, respiratory rate of 14 breaths/min, temperature of 36.5°C, anicteric, normal color. On palpation of the abdomen, he showed pain on deep palpation in the epigastric region without palpable masses and peristalsis present. No other findings were revealed on physical examination.

He brought an abdominal ultrasound, the result of which was normal, along with a negative fecal parasitology test. He denied having previously undergone upper gastrointestinal endoscopy or colonoscopy. As for his family history, he reported that his paternal grandfather died of stomach cancer. He reported a past pathological history without relevant details. He denied smoking and social drinking.

Diagnosis

An upper digestive videoendoscopy was requested, the report of which indicated endoscopic gastritis with marked flat erosions in the antrum, with eroded, bloody, intensely friable mucosa, extending to the *incisura angularis* and abrupt interruption of the mucous fold in the distal portion of the gastric body (**Figures 1, 2 and 3**).

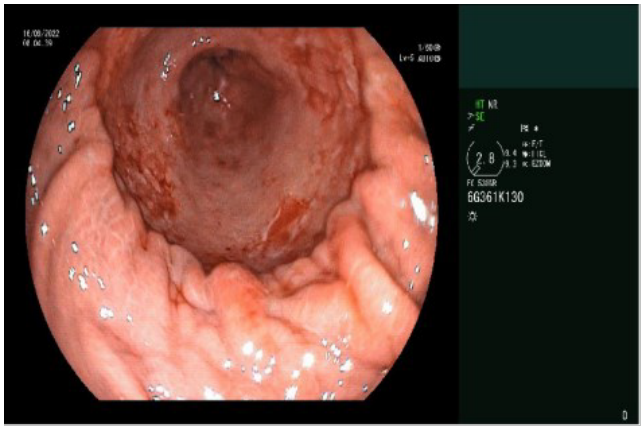

Source: Integrated Gastroenterology Center, 2023.

Figure 1. Gastric antrum.

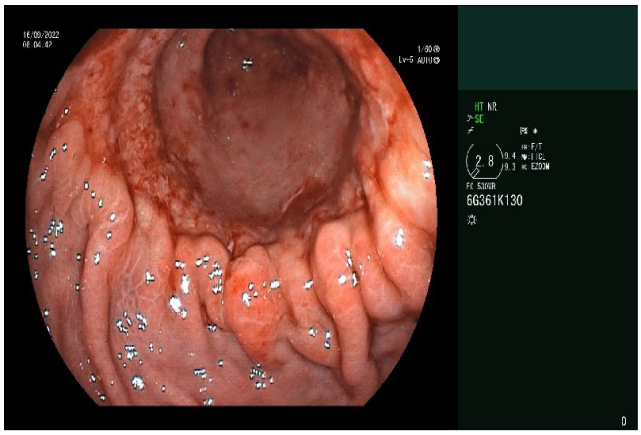

Source: Integrated Gastroenterology Center, 2023.

Figure 2. Distal portion of the gastric body

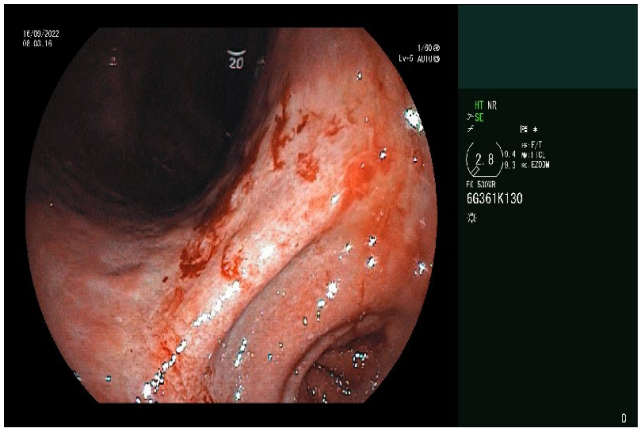

Figures 1 and 2 show antral mucosa with friability, edema and continuous flat erosions, extending to the *incisura angularis*, and an abrupt interruption of the mucosal fold in the distal portion of the body.
Source: Integrated Gastroenterology Center, 2023.

Figure 3. Incisura angularis.

Histopathological correlation was needed, so biopsies of the antrum and incisura *angularis* were also requested.

Histopathological results showed gastritis with marked erosions and ulcerations, the presence of a significant mixed inflammatory infiltrate in samples from the antrum and *incisura angularis*, with the involvement of histiocytes and plasma cells and with local loss of gastric gland components. The *Helicobacter pylori* test was positive. **Figure 4** shows ulcerated gastric mucosa on HE 200x, while **Figure 5** indicates plasmacytosis on HE immersion. **Figure 6** cells showed a lateralized nucleus and more apparent cytoplasm, indicating plasma cells.

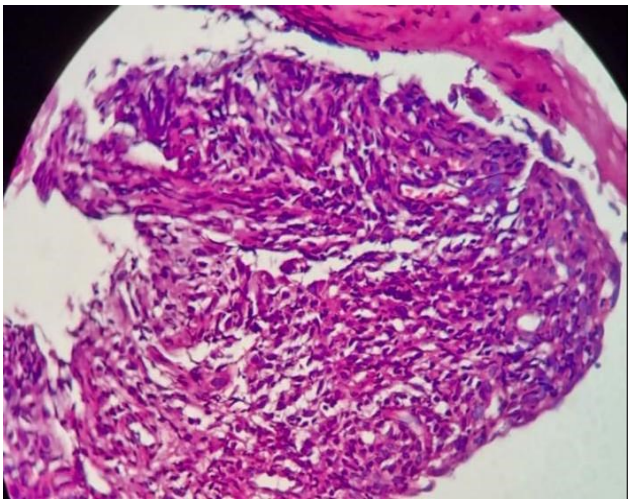

Source: Dr. Nilcimar, Pathology Studio Laboratory, 2023.

Figure 4. Ulcerated and edematous gastric mucosa.

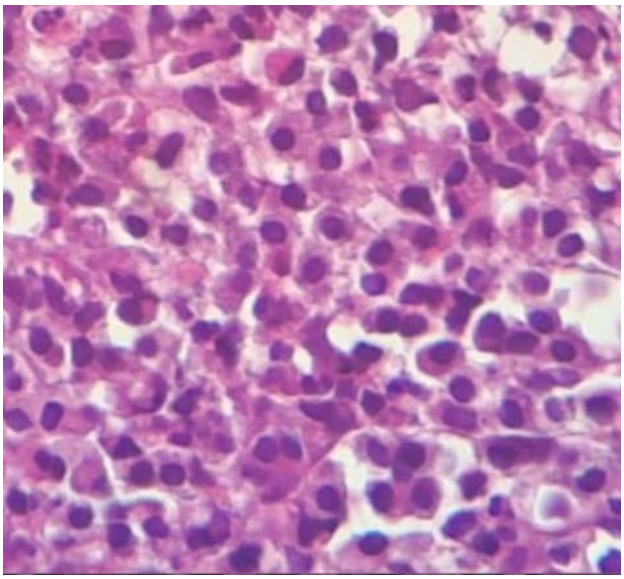

Source: Dr. Nilcimar, Pathology Studio Laboratory, 2023.

Figure 5. Presence of plasma cells in the gastric mucosa.

Considering the prevalence, it was recommended to systematically do VDRL and FTA-Abs tests in severe gastritis that occurs with increased plasma cell infiltration.

Laboratory serological tests were then carried out, which resulted in VDRL of 1/64 and FTA-Abs — IgM and IgG reactive, confirming activity of *T. pallidum* spirochetes in the gastric envelope, proving reactivity to the presence of antibodies by non-treponemal and treponemal serology.

Treatment

Following Ministry of Health regulations, three doses of benzathine penicillin 2,400,000 IU IM were prescribed, one every seven days, for a total of 7,200,000 IU, and the patient was asked to return to the clinic after completion of treatment for reevaluation. We opted for follow-up with three doses, as there was the presence of suspicious extragenital lesions without a clear definition of the time of infection, recommending the broadest form of treatment in this case.

Clinical follow-up

The patient returned six months after treatment to the gastroenterology clinic to undergo upper digestive videoendoscopy, the result of which showed moderate endoscopic enanthematous gastritis of the antrum without erosions (**Figures 7 and 8**). It demonstrated an aspect of complete remission in relation to the first examination,

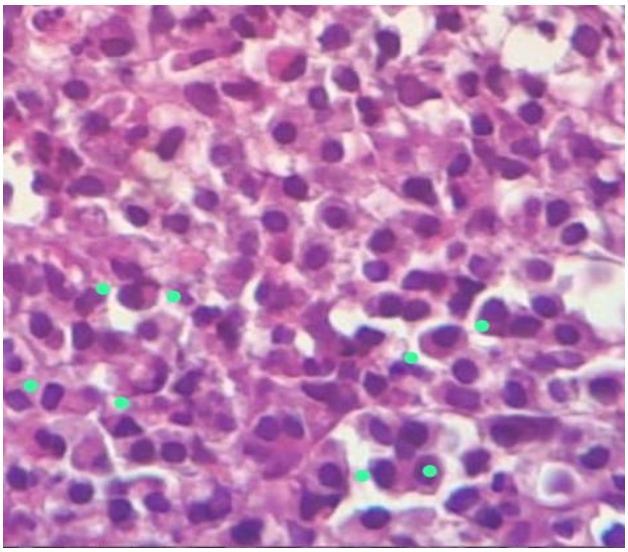

In Figure 4, histologically confirmed ulcerated and edematous gastric mucosa. In Figure 5, the presence of plasmacytes is confirmed, together with Figure 6, in which green spots indicate cells with a lateralized spherical nucleus, apparent basophilic cytoplasm, appearing in the locations of chronic inflammation, where these are the plasmacytes.

Source: Dr. Nilcimar, Pathology Studio Laboratory, 2023.

Figure 6. Presence of plasma cells in the gastric mucosa.

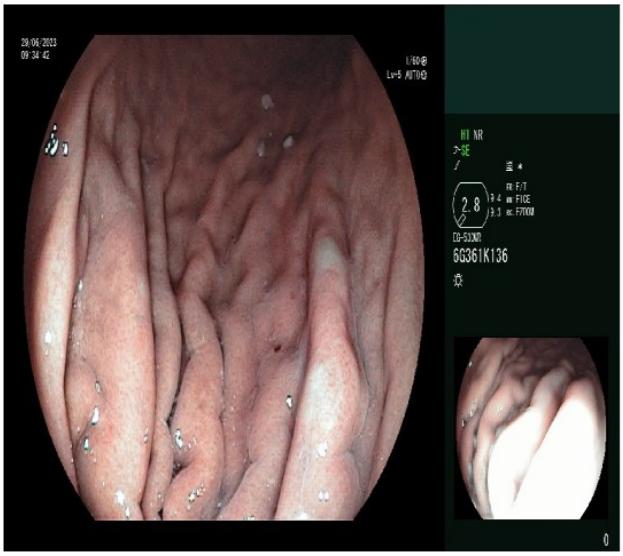

Source: Integrated Gastroenterology Center, 2023.

Figure 7. Gastric body after treatment.

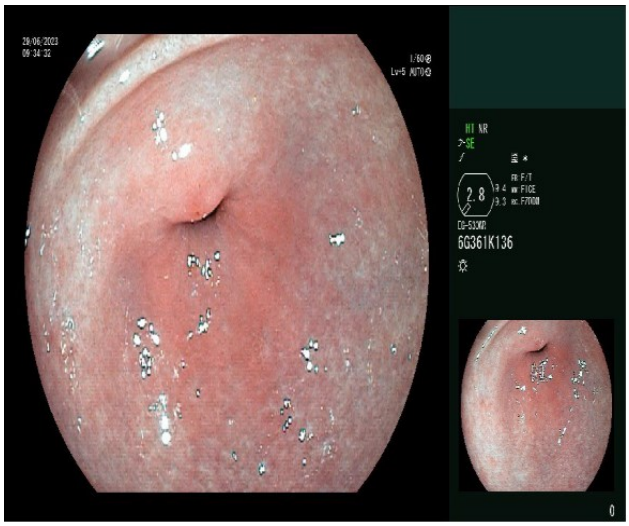

Figures 7 and 8 demonstrate the complete remission of the disease after the recommended treatment six months later. Note the disappearance of the erosions and ulcerations in both the antrum and gastric body previously evident. Confirmed by histology.
Source: Integrated Gastroenterology Center, 2023.

Figure 8. Pylorus and gastric antrum after treatment.

with treatment adhered correctly. Biopsies of the antrum and *incisura angularis* were again requested.

Histopathology of the biopsies was performed, with results of mild atrophy, lymphoid aggregates, complete intestinal metaplasia and absence of malignancy. The presence of *H. pylori* was still positive, and its eradication with standard treatment was indicated. In addition, the non-treponemal test was repeated for control with a VDRL result of 1/2.

DISCUSSION

Cases of gastric syphilis have been reported since the 19th century[4,5], with the majority mentioning common gastrointestinal symptoms, such as pain in the epigastric region, postprandial fullness, early satiety, nausea, vomiting and, one of the main ones, weight loss. Because of this, other more prevalent causes are taken into greater consideration at the time of diagnosis, as they have similar symptoms[4,5,9].

Common findings on endoscopic imaging are flat ulcerations, erosive gastritis of varying degree, nodularity, bleeding, hyperemia, hypertrophy of the already friable mucosa and the appearance of masses[6,10,11]. The most affected regions are the antrum and body and can extend to the pylorus[9,12]. However, each patient may present with a different clinical condition. A differential indicator would be the non-improvement of symptoms with the use of PPIs, something uncommon in other diseases, for example. Being aware of the patient's sexual life and whether he or she has already had any symptoms related to primary syphilis, such as painless hard chancre and diffuse adenopathy with skin rash, also helps to consider this possibility[4,5,7-9].

Most patients acquire syphilis through sexual transmission, and its spread to the gastrointestinal tract occurs hematogenously during the second phase of the disease, not through ingestion, as some may think[10,13]. Laboratory tests are extremely important in suspected diagnosis, along with immunohistochemical tests such as PCR, with both VDRL and FTA-Abs being recommended. The first, non-treponemal, is indicated for initial screening of the disease and the second, treponemal, to confirm the diagnosis[4,5,7,13].

Generally, syphilis is also accompanied by HIV infection; after all, immunosuppressed patients are more likely to have more severe and non-specific symptoms, but there is not always this correlation, as was the case reported. Delay in diagnosis can cause lesions to evolve into malignant neoplasms[6,10,13].

As lesions of the antrum and gastric body must be biopsied, histopathological findings commonly show active chronic erosive gastric mucosa, which may even involve the submucosal layer, thickening of the wall of intramucosal blood vessels, vasculitis, a variability of inflammatory cells and infiltration of both plasma cells and lymphocytes[6,7,10]. Plasma cell infiltration, despite being a major inflammatory cofactor in syphilis, is not considered pathognomonic, and the professional should pay attention to other possible findings, if this is not present[10]. Due to the non-specific clinical nature, these findings are confused with lymphoma, gastric cancer, chronic gastritis, complicated peptic ulcers and even autoimmune diseases, leading to harmful solutions for the patient, such as delayed treatment and even surgeries, for example[6,10,14].

Once the diagnosis is confirmed, treatment is considered a secondary phase. Thus, intramuscular injection of benzathine penicillin G with 2,400,000 IU is made once a week for three weeks. Its standard treatment has demonstrated great effectiveness in remitting systemic symptoms in around 3 to 5 days, and gastrointestinal symptoms in 7 to 10 days. The gastric lesions completely disappeared in approximately 1 to 3 months, which was observed during control endoscopy and publicly reported in most similar cases[10,13,15]. In some cases, where there has been a delay in diagnosis or failure to adhere to treatment and where the stage of the disease progresses, resolving surgery is recommended[5,6,10,13,15].

Strengths

"The histopathological findings were compatible with responses to syphilis and with serological tests (non-treponemal and treponemal), together with endoscopic/histopathological tests (performed by the same specialists) before and after the classic treatment for syphilis — contributing to the diagnosis and control of the disease. Although we did not have confirmation with the genetic detection of *T. pallidum* molecular biology assay (PCR), we believe that our report serves to strengthen the classic thoughts: syphilis is the great imitator and it is worth, even in 2024, thinking in syphilis mode."

Limitations

Molecular biology analysis (PCR) of surgical specimens for identification of the etiological agent of syphilis would be important. However, it is worth noting that extragenital/late lesions of syphilis can occur without the presence of the bacteria.

CONCLUSION

Even though this is a rare form of the disease, one should always be aware of possible differential diagnoses. It is of utmost importance to compile a detailed history and correlate the clinical history with the imaging examinations, in addition to follow-up of the patient up to fully resolving the case, to avoid unnecessary surgical interventions and procedures[16].

Participation of each author

AXR: Conceptualization, Investigation, Methodology, Project administration, Validation. MASS: Conceptualization, Methodology, Project administration, Supervision, Validation. RA: Data curation, Formal Analysis, Resources, Validation. NLM: Conceptualization, Investigation, Methodology, Project administration, Supervision, Validation. ABR: Conceptualization, Investigation, Methodology, Project administration, Supervision, Validation. PRRC: Conceptualization, Investigation, Methodology, Project administration, Supervision, Validation. ABRM: Conceptualization, Investigation, Methodology, Project administration, Supervision, Validation. LBC: Investigation, Project administration. PHXR: Investigation, Project administration.

Funding

The authors declare no financial support.

Conflicts of interest

The author declared no potential conflicts of interest with respect to the research, authorship, and/or publication of this article.

REFERENCES

1. Brito T, Lima T, Cunha-Oliveira A, Noronha A, Brito C, Farias F, et al. Salus platform: a digital health solution tool for managing syphilis cases in Brazil – a comparative analysis. Int J Environ Res Public Health. 2023;20(7):5258. https://doi.org/10.3390/ijerph20075258
2. Ferreira-González L, Rubin EP, Álvarez-Fernández JC, Caínzos-Romero T. Gastritis sifilítica: una etiología a tener en cuenta. Enferm Infecc Microbiol Clin. 2012;30(2):105-7. https://doi.org/10.1016/j.eimc.2011.11.001
3. Pinheiro YT, Silva RAR. Has the COVID-19 pandemic affected the epidemiology of syphilis in Brazil? Rev Bras Ginecol Obstet. 2022;44(6):629-30. https://doi.org/10.1055/s-0042-1748024
4. Osman M, Hasan S, Azher Q, Elbedawi M, Bachuwa G. Syphilitic gastritis: a rare presentation of secondary syphilis. BMJ Case Rep. 2018;2018:bcr2017223868. https://doi.org/10.1136/bcr-2017-223868
5. Cao J, Zhu J, Xiang Y, Peng P, Liu Q, Fu H, et al. Gastric syphilis mimicking lymphoma: a case report. Infect Drug Resist. 2023;16:4539-44. https://doi.org/10.2147/IDR.S414976
6. Lan YM, Yang SW, Dai MG, Ye B, He FY. Gastric syphilis mimicking gastric cancer: a case report. World J Clin Cases. 2021;9(26):7798-804. https://doi.org/10.12998/wjcc.v9.i26.7798
7. Yu HJ, Kim SJ, Oh HH, Im CM, Han B, Myung E, et al. Case report of gastric syphilis in Korea: clinical features, pathology, management, and prognosis. Medicine (Baltimore). 2021;100(50):e28212. https://doi.org/10.1097/md.0000000000028212
8. Okamoto K, Hatakeyama S, Umezawa M, Hayashi S. Gastric syphilis: the great imitator in the stomach. IDCases. 2018;12:97-8. https://doi.org/10.1016/j.idcr.2018.03.015
9. Ramos Jr. AN. Persistência da sífilis como desafio para a saúde pública no Brasil: o caminho é fortalecer o SUS, em defesa da democracia e da vida. Cad Saúde Pública. 2022;38(5):PT069022. https://doi.org/10.1590/0102-311XPT069022
10. Assarzadegan N, Fang JM, Voltaggio L, Riddell RH, Montgomery EA, McDonald OG, et al. Histologic features of syphilitic gastritis: a rare but resurging imitator of common diseases. Am J Clin Pathol. 2023;159(3):263-73. https://doi.org/10.1093/ajcp/aqac153
11. Silva BDV, Faustini HVNC, Diniz TCAP, Marques FH, Aguiar PH, Villela MRP, et al. Sífilis gástrica: desafios do diagnóstico e relato de caso. Brazilian Journal of Health Review. 2022;5(5):20534-9. https://doi.org/10.34119/bjhrv5n5-220
12. Chadu Júnior JB, Oliveira JA, Violatti Filho JR, Amâncio FM, Resende RP, Chadu ILSJ. Sífilis gástrica. Relatos Casos Cir. 2018;4(2):e1729. https://doi.org/10.30928/2527-2039e-20181729
13. Guimarães TF, Novis CFL, Bottino CB, D'Acri AM, Lima RB, Martins CJ. Gastric syphilis – case report. An Bras Dermatol. 2016;91(5):670-2. https://doi.org/10.1590/abd1806-4841.20164174
14. Brasil. Ministério da Saúde. Secretaria de Vigilância em Saúde e Ambiente. Boletim Epidemiológico. Sífilis [Internet]. Brasília: Ministério da Saúde; 2023 [cited on 2024 April 22]. Available from: https://www.gov.br/saude/pt-br/centrais-de-conteudo/publicacoes/boletins/epidemiologicos/especiais/2023/boletim-epidemiologico-de-sifilis-numero-especial-out.2023/view
15. Dourra M, Mussad S, Capatina-Rata AM. An unusual case of syphilis with abdominal pain. Cureus. 2021;13(8):e16806. https://doi.org/10.7759/cureus.16806
16. Goldim JR, Fleck MP. Ética e publicação de relatos de caso individuais. Rev Bras Psiqu. 2010;32(1):2-3.

Address for correspondence
ARTHUR XAVIER RAPHAEL
Rua Aníbal Couto, 49 – Santa Rosa
Barra Mansa (RJ), Brazil
CEP: 27323-130
E-mail: axr123a@gmail.com

Received on: 04.18.2024
Approved on: 06.28.2024

This is an open access article distributed under the terms of the Creative Commons license.