

Preprint

<https://doi.org/10.5327/DST-2177-8264-1473> DST - J bras Doenças Sex Transm 2025;37:e1473

Artigo Original

**MPOX IN PATIENTS ATTENDED IN THE SEXUALLY TRANSMITTED DISEASES SECTOR OF THE UNIVERSIDADE FEDERAL FLUMINENSE IN THE MUNICIPALITY OF NITERÓI, RJ, BRAZIL**

***MPOX EM PACIENTES ATENDIDOS NO SETOR DE DOENÇAS SEXUALMENTE TRANSMISSÍVEIS DA UNIVERSIDADE FEDERAL FLUMINENSE NO MUNICÍPIO DE NITERÓI, RJ, BRASIL***

Wilma Nancy Campos Arze<sup>1</sup> <https://orcid.org/0000-0002-2620-0620>, Izabel Christina Nunes de Palmer Paixão<sup>2</sup> <https://orcid.org/0000-0001-7513-2567>, Claudio Cesar Cirne dos Santos Pessanha<sup>3</sup> <https://orcid.org/0000-0001-8376-1830>, Caroline de Souza Barros<sup>4</sup> <https://orcid.org/0000-0002-4678-3093>, Kíssila Rabelo<sup>5</sup> [0000-0001-7579-7788](https://orcid.org/0000-0001-7579-7788), Maurício de Souza Leão<sup>6</sup>, Hugo Boechat Andrade<sup>7</sup> <https://orcid.org/0000-0001-6781-6125>, Ingrid Antunes da Silva<sup>8</sup> <https://orcid.org/0000-0003-0905-0197>, Christina Thereza Machado Bittar<sup>9</sup> <https://orcid.org/0000-0003-2839-9677>, Jorge José de Carvalho<sup>10</sup>, Aline Gissele Azevedo Ferreira Goulart<sup>11</sup> <https://orcid.org/0009-0004-2010-0233>, Lucas Gabriel Cabrera Campos<sup>12</sup> [0009-0002-5271-7882](https://orcid.org/0009-0002-5271-7882), Adriel Chihyung Chung Campos<sup>13</sup> <https://orcid.org/0000-0002-5120-4367>, Mauro Romero Leal Passos<sup>14</sup> <https://orcid.org/0000-0002-6183-7985>

**Título curto: MPOX IN PATIENTS FROM THE STI SECTOR OF UFF, NITERÓI, RJ, BRAZIL**

## ABSTRACT

**Introduction:** Mpox, formerly known as monkeypox, is caused by the double-stranded DNA MPXV virus of the *Poxviridae* family, *Orthopoxvirus* genus. It has two known clades: West Africa and Congo Basin. It is a zoonosis similar to smallpox that has reemerged globally, with numerous cases reported worldwide

in 2022. **Objective:** To describe sociodemographic, behavioral, clinical, and laboratory characteristics of suspected and confirmed mpox cases attended in the Sexually Transmitted Diseases (STD) Sector of the Fluminense Federal University (UFF), Niterói, RJ, Brazil. **Methods:** The STD/UFF sector is a public open-access reference center for STDs, with no appointment regulation. This is a prospective, observational cohort study of suspected and confirmed MPXV cases attended at STD/UFF between June 2022 and March 2024. Clinical samples (lesions) were collected for diagnostic confirmation by MPXV RT-PCR (public laboratory – LACEN-RJ), along with rapid tests for syphilis, HIV, and hepatitis B and C. **Results:** Among 33 individuals with suspected mpox, 20 (60.6%) were confirmed. Compared to non-confirmed cases, confirmed cases were more frequent among unvaccinated individuals aged 21–39 years, cisgender men (70% vs. 69.15%;  $p < 0.015$ ), Black individuals (55% vs. 45%;  $p = 0.449$ ), residents of São Gonçalo (50% vs. 30.8%;  $p = 0.335$ ), those with higher education (45% vs. 30.8%;  $p = 0.429$ ), and men who have sex with men (MSM) (80% vs. 53.84%;  $p = 0.508$ ). They were more likely to have a non-exclusive steady partner (50% vs. 7.69%;  $p = 0.233$ ), good knowledge and preventive practices regarding STIs (75% vs. 46.15%;  $p = 0.204$ ), to use condoms occasionally (80% vs. 61.54%;  $p = 0.500$ ), to have been referred by a health professional (70% vs. 61.54%;  $p < 0.041$ ), and to have syphilis as the main differential diagnosis (30% vs. 30.77%;  $p = 0.415$ ). Confirmed cases more often presented genital (60% vs. 39.8%) and anal lesions (85% vs. 30.8%) and systemic symptoms (93.2% vs. 69.3%) than non-confirmed ones. Forty-five percent were HIV-positive white males over 32 years old, MSM, with anal lesions, and 33.33% were diagnosed with syphilis. Among mpox-positive cases, 27% reported PrEP use and 9% PEP use. Of these, 65% had their sexual partners examined at STD-UFF, with 38.46% testing positive for mpox. There were no severe cases or hospitalizations. **Conclusion:** mpox in Rio de Janeiro rapidly evolved into a local epidemic, with sexual contact playing a crucial role in its spread, and higher incidence among MSM and people living with HIV (PLHIV). The rate of sexual partner consultation and testing in our service was high, and comorbidity with syphilis was frequent.

**Keywords:** Mpox, Monkeypox, STD, STI, PCR, Diagnosis

## RESUMO

**Introdução:** Mpox antes monkeypox, é causada por MPXV de DNA de fita dupla da família Poxviridae, gênero Orthopoxvirus. Tem dois clados conhecidos, África Ocidental e Bacia do Congo. É uma zoonose semelhante à varíola e reemergiu mundialmente, com muitos casos no mundo, em 2022. **Objetivo:** Descrever características sociodemográficas, comportamentais, clínicas e laboratoriais de uma série de casos suspeitos e confirmados de mpox atendidos no Setor de DST da Universidade Federal Fluminense, Niterói, RJ (DST/UFF). **Métodos:** DST/UFF é centro de referência pública, porta aberta, sem regulação na área de DST. É um estudo de coorte prospectiva e observacional de uma série de casos suspeitos e confirmados de MPVX atendidos no DST/UFF. Incluímos todos os pacientes atendidos com suspeita de mpox entre o período de 6/2022 a 3/2024. Coletamos amostras clínicas (lesões) para a confirmação diagnóstica por RT-PCR de MPVX (laboratório público – LACEN-RJ) e testes rápidos para sífilis, HIV, hepatites B e C. **Resultados:** De 33 pessoas com suspeita de mpox, 20 (60,6 %) foram confirmados. Comparado com os casos não confirmado, os casos confirmados foram mais frequentes entre pessoas não vacinadas contra varíola de 21 a 39 anos, homens cisgêneros (70% vs. 69,15%;  $p < 0.015$ ), raça/cor negro (55%vs.45%  $p = 0.449$ ), morador de São Gonçalo (50% vs. 30,8%  $p = 0,335$ ), com grau de escolaridade superior completo (45% vs.30,8%  $p = 0,429$ ), HSH (80% vs 53,84%  $p = 0,508$ ), com parceiro fixo não exclusivo (50% vs. 7,69%  $p = 0,233$ ), com bom conhecimento de atitudes e práticas de prevenção das IST (75% vs. 46,15%  $p = 0,204$ ) e faz uso de preservativo às vezes (80% vs. 61,54%  $p = 0,500$ ), estes foram encaminhados por profissional da saúde (70% vs. 61,54%  $p < 0,041$ ), e tem a sífilis como principal diagnóstico diferencial (30% vs. 30,77 %  $p = 0,415$ ). Os casos confirmados apresentaram mais lesões genitais (60% vs. 39,8%) e anais (85% vs.30,8%) e sinais e sintomas sistêmicos (93,2% vs. 69,3%) do que os casos não confirmados. 45 % eram pessoas vivendo com HIV brancos do sexo masculino com idades acima de 32 anos, HSH e apresentaram lesões na região anal e 33.33% tiveram diagnóstico de sífilis. O uso de PrEP (27% vs.23%); PEP (9%) nos casos positivos para mpox. Dos casos positivos 65% tiveram a parceria sexual examinada no DST-UFF. Dessas 38,46%

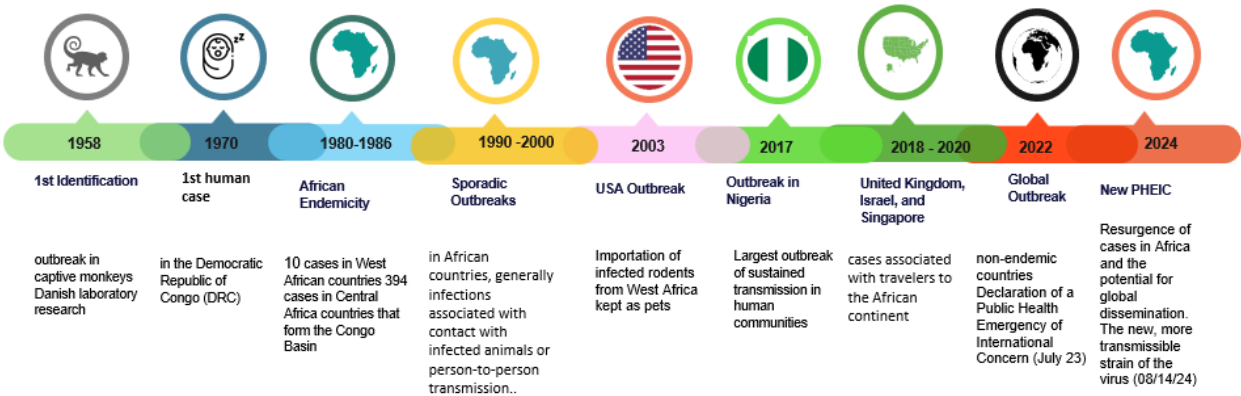
foram positivos de mpox, não tivemos casos graves e nenhuma internação foi necessária. **Conclusão:** A mpox no Rio de Janeiro evoluiu rapidamente para uma epidemia local, com o contato sexual sendo crucial na sua disseminação e maior incidência em HSH e em PVHIV. Foi alta a porcentagem de consulta/exame de parceria sexual, no nosso serviço. A comorbidade com sífilis foi alta.

**Palavras-chave:** Mpox, Monkeypox, DST, IST, PCR, Diagnóstico.

INTRODUCTION

The recent public health crisis caused by SARS-CoV-2, the agent behind COVID-19, prepared the world for the emergence of new infectious threats. However, the global rise of monkeypox cases, renamed mpox by the World Health Organization (WHO), starting in 2022, and its declaration as a Public Health Emergency of International Concern (PHEIC), revealed challenges and epidemiological dynamics that diverge from what was historically known about the disease.<sup>1,2</sup> Although the Monkeypox Virus (MPXV) was identified over 60 years ago (Figure 1).

Figure 1: Historical and geographical chronological evolution of mpox cases globally from its emergence to the present.



Source: prepared by the author, 2024.

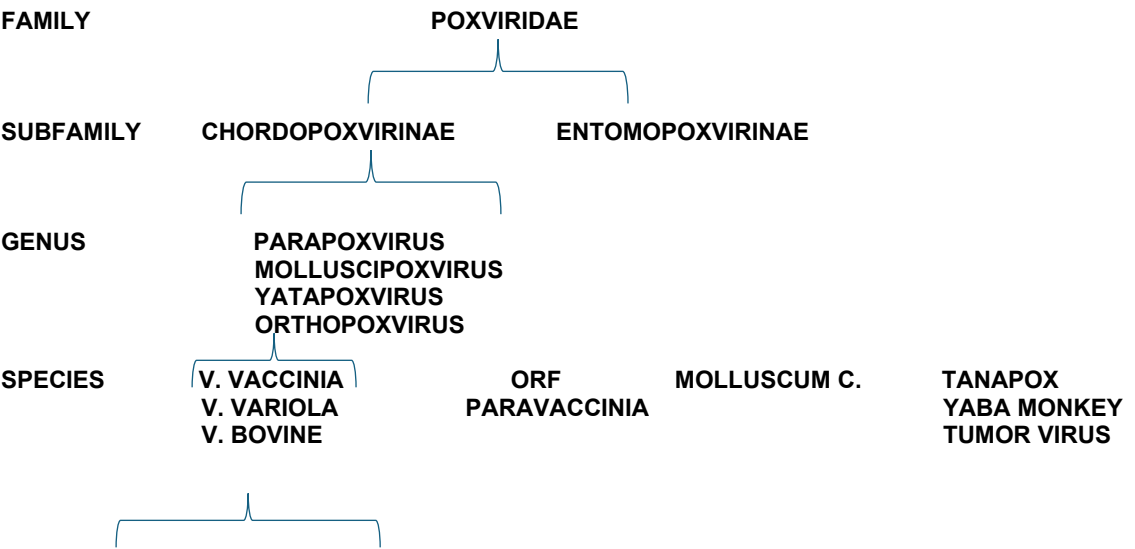
Its recent and accelerated spread to non-endemic countries, especially with the notable occurrence of new cases in Central Africa starting in 2024, demands a deeper understanding of its natural history, host-agent interactions, and transmission mechanisms.<sup>3,4</sup> The rapid expansion of mpox highlighted the urgency of obtaining evidence on its new clinical presentations and possible outcomes, in order to support the development of effective diagnostic and treatment strategies. The transition in nomenclature from "monkeypox" to "mpox"<sup>5</sup> was a crucial step in combating the stigmatization of animals and population groups, preventing the repetition of prejudiced discourses and behaviors that marked other epidemics, such as AIDS.<sup>6,7</sup>

The situation becomes even more critical with Brazil ranking second in the number of cases in the Americas, second only to the United States.<sup>8</sup> On August 14, 2024, the World Health Organization (WHO) declared a new Public Health Emergency of International Concern (PHEIC). This announcement marks a global alert for the resurgence of the disease, driven by a new and dangerous viral strain.

In the Genomic and Evolution analysis of the Monkeypox Virus (MPXV), it belongs to the genus *Orthopoxvirus* (OPV) of the *Poxviridae* family and the subfamilies *Entomopoxvirinae* and *Chordopoxvirinae*. There are four main genera that include species that are more commonly known to infect humans, along with the smallpox virus (VARV), the vaccinia virus (VACV), the camelpox virus (CMPV), and the cowpox virus (CPXV).<sup>9,10</sup>

The *Poxviridae* family is composed of double-stranded DNA (dsDNA) genetic material, capable of infecting mammals, insects, reptiles, and birds. It ranges in size from 200 to 250 nm in diameter, which allows its identification by electron microscopy magnified approximately 10,000.<sup>11,12</sup> It consists of 22 genera and 83 species across two subfamilies: Chordopoxvirinae (18 genera and 52 species) and Entomopoxvarinae (4 genera and 31 species).<sup>13,14</sup> (Figure 2).

Figure 2: Taxonomic classification of Monkeypox in the evolutionary lineage of the *Poxviridae* family.



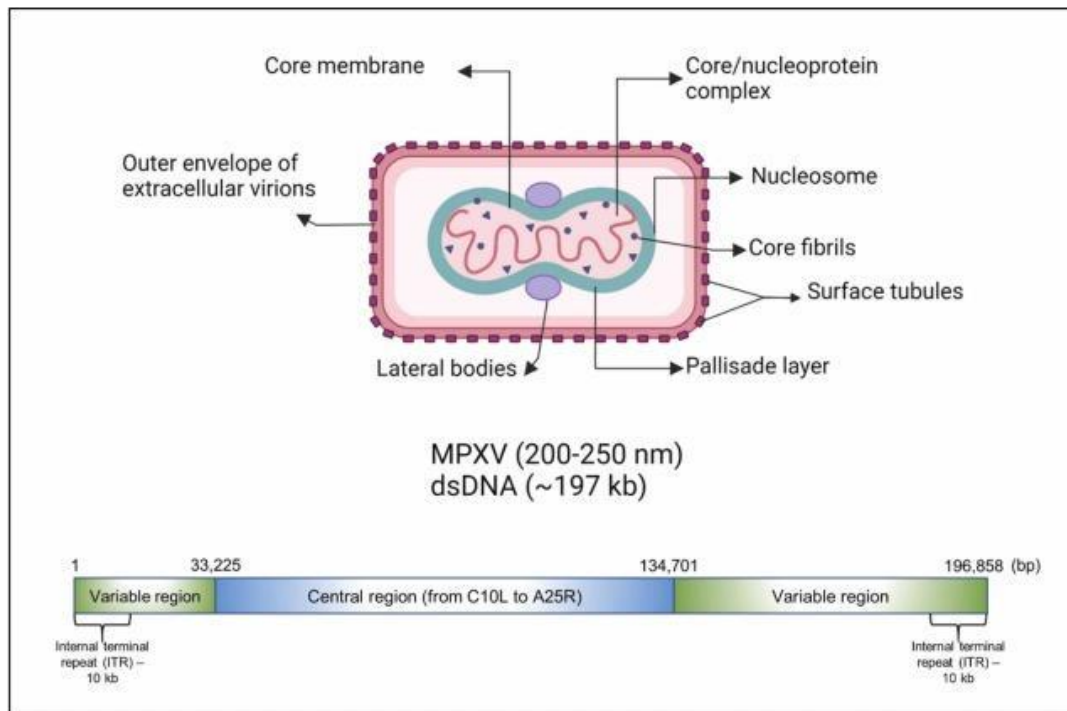
## COWPOXVIRUS MPXV

Clade I (AC|BC)  
Clade II (AO)- IIa and IIb

Source: Adapted by the author from Kaler J, 2022.<sup>13,14</sup>

The Poxviridae family constitutes a group of viruses characterized by having a large viral particle, variable in size between 200 and 300 nm, enveloped, and containing double-stranded DNA (dsDNA). Electron microscopes portray their unique structure as oval or rectangular entities of variable size.<sup>15,16</sup> Among all animal viruses, poxviruses possess the largest and most complex DNA genomes.<sup>17,18</sup> There are four main virion elements: core, lateral bodies, outer membrane, and lipoprotein outer envelope.<sup>19,20</sup> The central core contains the viral dsDNA and core fibrils. The monkeypox virus genome consists of 197kb, with the central genomic region comprising 101kb. Both terminal variable regions include a terminal inverted repeat ITR of 6379 bp with a hairpin loop approximately 80 bp long, short tandem repeats of 70 or 54 bp, and unique ITR sequences NR 1 and NR 2, and the coding region. The virus contains about 190 non-overlapping open reading frames ORFs, four of which are located in the UTR sequence.<sup>21,22,23,24</sup> (Figure 3)

Figure 3: Viral particle and genome structure of MPXV of the Chordopoxvirinae subfamily.



Source: Karagoz A, H. Tombuloglu, M. Alsaeed *et al.*<sup>15,16</sup>

Recent genomic studies have revealed that the 2022 outbreak virus accumulated around 50 single-nucleotide polymorphisms (SNPs) compared to previous strains, an unexpectedly high mutation rate for an *Orthopoxvirus*. Mutational analysis suggests a predominance of GA>AA and TC >TT type mutations, which are consistently associated with the activity of viral genome editing enzymes, such as those from the APOBEC3 family.

Unlike the 2022 outbreak, which was largely driven by the West African clade (Clade IIb), the new emergency is centered on the spread of Clade Ib, a new variant of Clade I (Congo Basin). This strain, historically associated with higher virulence and elevated fatality rates (up to 10 %).<sup>5,25,26,27,28,29</sup> is spreading with an alarming dynamic, primarily through sexual networks. Although the majority of cases are concentrated in the Democratic Republic of Congo (**DRC**), with over 15,600 cases and 537 deaths registered in 2024, Clade Ib has been detected in neighboring countries such as Burundi, Kenya, Rwanda, and Uganda, which had no previously reported mpox cases. The distinction is between the viral clades — the more virulent Clade I (Congo Basin) and Clade II (West Africa).

The recent PHEIC declaration by the WHO in August 2024 reinforces the severity of the situation with the spread of a new Clade I strain, Clade 1b, in Central Africa, with transmission characteristics that appear to be predominantly linked to sexual networks.<sup>30</sup> Differences in MPXV virulence are caused by variations in the genome, including deletions of genetic regions and fragmentation in open reading frames, which suggests viral adaptation.<sup>31</sup> The biosynthesis of MPXV, which occurs in the cytoplasm of the host cell, and the diversity of its infectious particles — extracellular virions (EVs) and mature virions (MVs) — are crucial aspects for understanding its replication and dissemination.<sup>19,32</sup> Transmission can occur zoonotically, from animal to human, but person-to-person spread, through direct contact with lesions, bodily fluids, respiratory droplets, and, more recently, intimate contact, reveals the complexity of control.<sup>29,30</sup>

## EPIDEMIOLOGY OF MPOX

In some countries, the occurrence of cases was considered to be **community human transmission**, leading to the institution of a mandatory quarantine of around 21 days for mpox cases, as happened in Belgium on May 20, 2022, with only four confirmed cases.<sup>33</sup>

According to a WHO report, the number of cases reported globally during the period of January 1, 2022, to March 31, 2024, amounted to a cumulative total of 95,226 confirmed cases.

lab-confirmed mpox cases, including 185 deaths, were reported to WHO, distributed across 117 countries/territories/areas (hereafter "countries") in all six WHO Regions. The majority of cases in March 2024 were reported in the African Region (39%), the European Region (26%), and the Region of the Americas

(25%), with the United States and Brazil being the countries with the highest cumulative number of cases of the disease. The decline in reporting must therefore be interpreted with caution.<sup>30</sup>

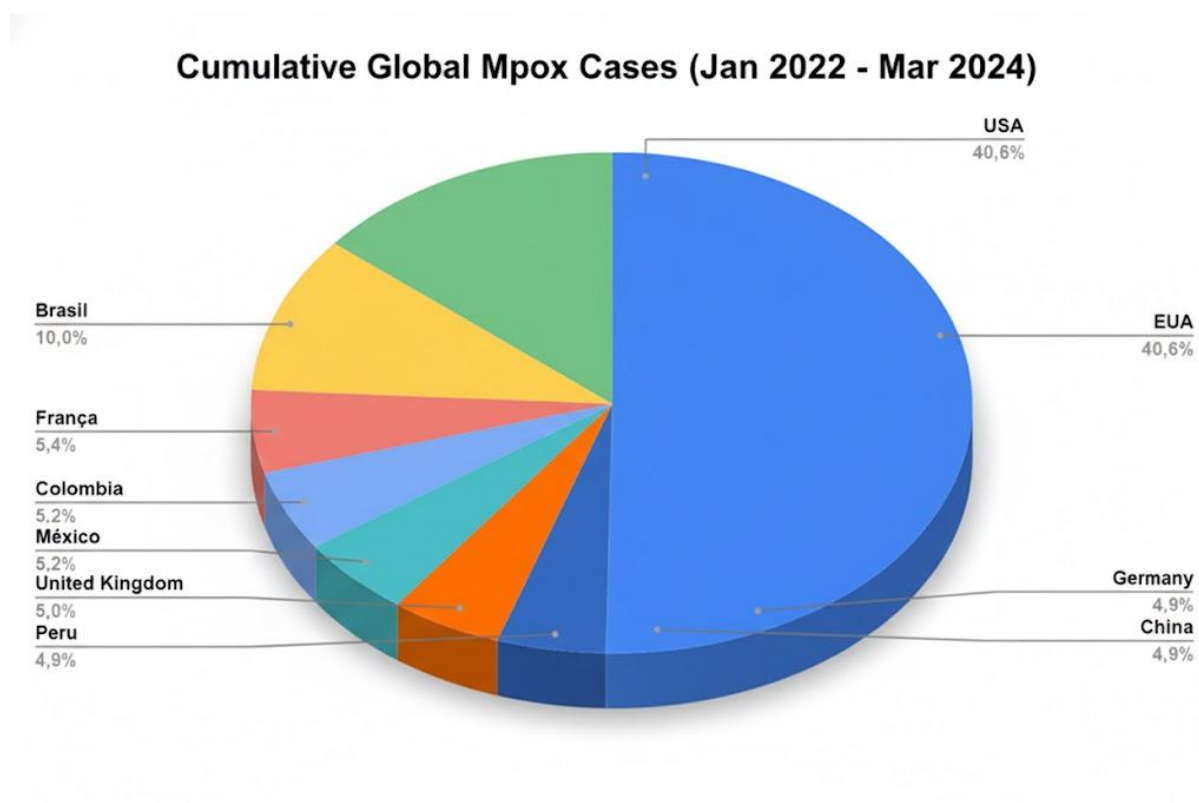
The epidemiological update provides a summary of the situation in the Americas of cases reported to PAHO/WHO: from the first cases presented in 2022 until August 17, 2024, there were 63,270 confirmed mpox cases, including 141 deaths, reported in 32 countries and territories of the Region of the Americas.<sup>30</sup> In 2022, the highest proportion of cases was recorded during the outbreak (90%), with the greatest number of cases reported in Epidemiological Week (EW) 32. A progressive decrease in the number of cases has been observed since then, although a slight increase in cases was recorded during EW 48 of 2022, the downward trend continued throughout 2023 and 2024.

As of March 31, 2024, the ten countries that have reported the highest cumulative number of cases globally are: the United States of America (n = 31,904), Brazil (n = 10,967), Spain (n = 7,960), France (n = 4,206), Colombia (n = 4,090), Mexico (n = 4,084), the United Kingdom (n = 3,908), Germany (n = 3,830), Peru (n = 3,812), and China (n = 3,812). (Figure 4)

In South America, 10 countries registered 22,990 mpox cases and 44 deaths between 2022 and August 17, 2024. Brazil concentrated 49% of the cases, followed by Colombia (19%) and Peru (17%).<sup>34</sup>

Figure 4: Cumulative global number of confirmed mpox cases reported, by WHO region, from January 1, 2022, to March 31, 2024.





Source: Adapted [by the author] from WHO 2024 Multi-country outbreak of mpox April 2024.<sup>30</sup>

The first confirmed case in Brazil was on June 9, 2022, in São Paulo, in a 41-year-old male resident of São Paulo with a travel history to Europe.

In Rio de Janeiro, the first imported case was identified on June 15, 2022, in a 38-year-old male patient, a resident of Rio de Janeiro, with a travel history to London. The first death was confirmed on July 28, 2022. This was a 33-year-old male patient, resident of Campos dos Goytacazes, who was immunosuppressed. (Figure 5)

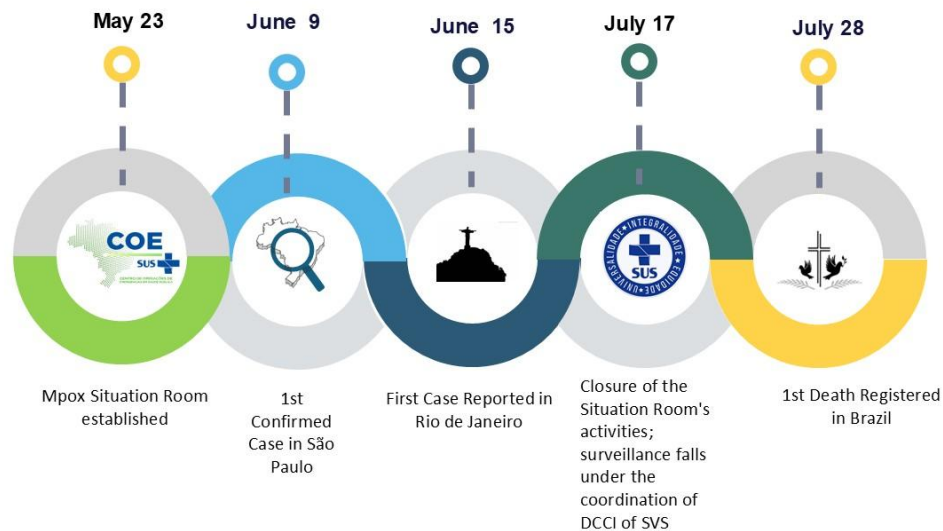
A total of 3,668 mpox notifications were registered in Rio de Janeiro until March 11, 2024. Of the total notifications received: 1,194 (32.5%) were confirmed for mpox; 2,279 (62.1%) were discarded; 58 (1.5%) were classified as probable; and 134 (3.6%) were suspected.

The highest registration of notifications occurred between Epidemiological Weeks (EW) 29 and EW 35 of 2022, with the case curve showing that the peak of cases was recorded in EW 30 of 2022, ending with 93 confirmed mpox cases.

Cases reported up to Epidemiological Week 43 in the Metropolitan Region 2, which includes Niterói, São Gonçalo, Maricá, and Itaboraí, accounted for 128 (13.79%) of the cases reported in Rio de Janeiro, data recorded in the panel of

the Center for Strategic Information and Health Surveillance Response (CIEVS) of the State Health Secretariat (SES).

Figure 5: Chronological evolution of the mpox epidemic response in Brazil between 2022 and 2024.



Source: Prepared by the author, 2024.

## TRANSMISSION

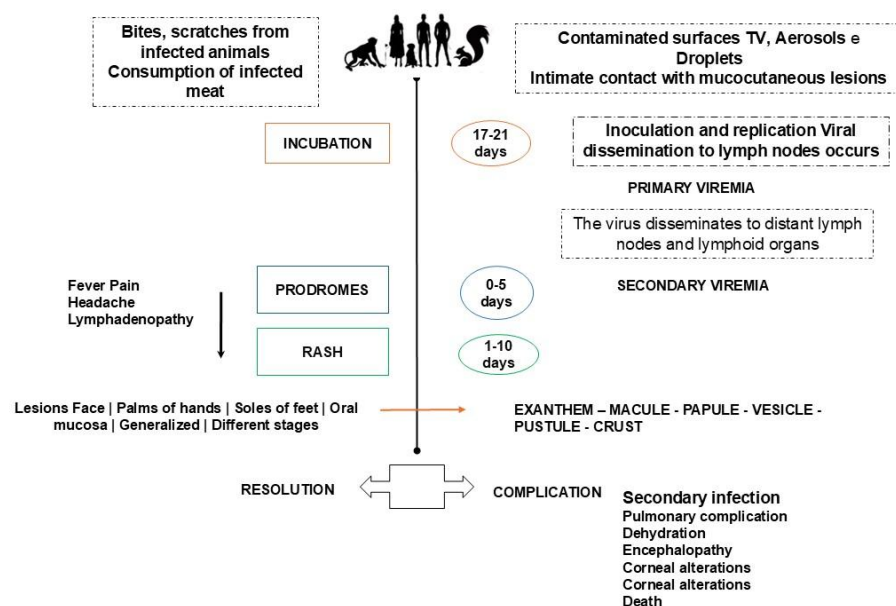
Transmission can occur in various ways: animal-to-animal, animal-to-human, or human-to-human (Figure 6). It can also occur in the case of pregnancy as maternal-fetal transmission, with potentially severe outcomes, increasing maternal and perinatal morbidity and mortality.<sup>35,36</sup>

Animal-to-human transmission can occur through direct contact with infected animals, whether through scratches, bites, or during activities such as hunting, preparing, and consuming contaminated wild animal meat.<sup>31</sup>

Human-to-human transmission was first documented in Nigeria and West Africa in 2018.<sup>37</sup> A subsequent outbreak in the U.S. in 2003 was associated with contact with sick prairie dogs.<sup>38</sup> Person-to-person transmission occurs primarily through direct contact via respiratory droplets, hugs, kisses, oral, anal, and vaginal sexual intercourse (receptive and insertive), or direct contact with skin lesions, rashes, scabs, or bodily fluids (secretions, blood), or indirect contact with recently contaminated surfaces and objects such as dishes, cutlery, bedding, and towels, which are believed to increase the risk of viral transmission among household members or from imported cases or cases related to travel to endemic regions.<sup>29,39,40</sup>

The epidemiological investigation of mpox presents significant challenges, particularly due to the difficulty in tracing the entire chain of transmission, especially in environments characterized by intense human-to-human and human-to-animal interaction.<sup>41</sup>

Figure 6: Mpox transmission, evolution, symptom manifestation, and outcomes.



Source: Prepared by the author, 2024.

## **SYMPTOMATOLOGY**

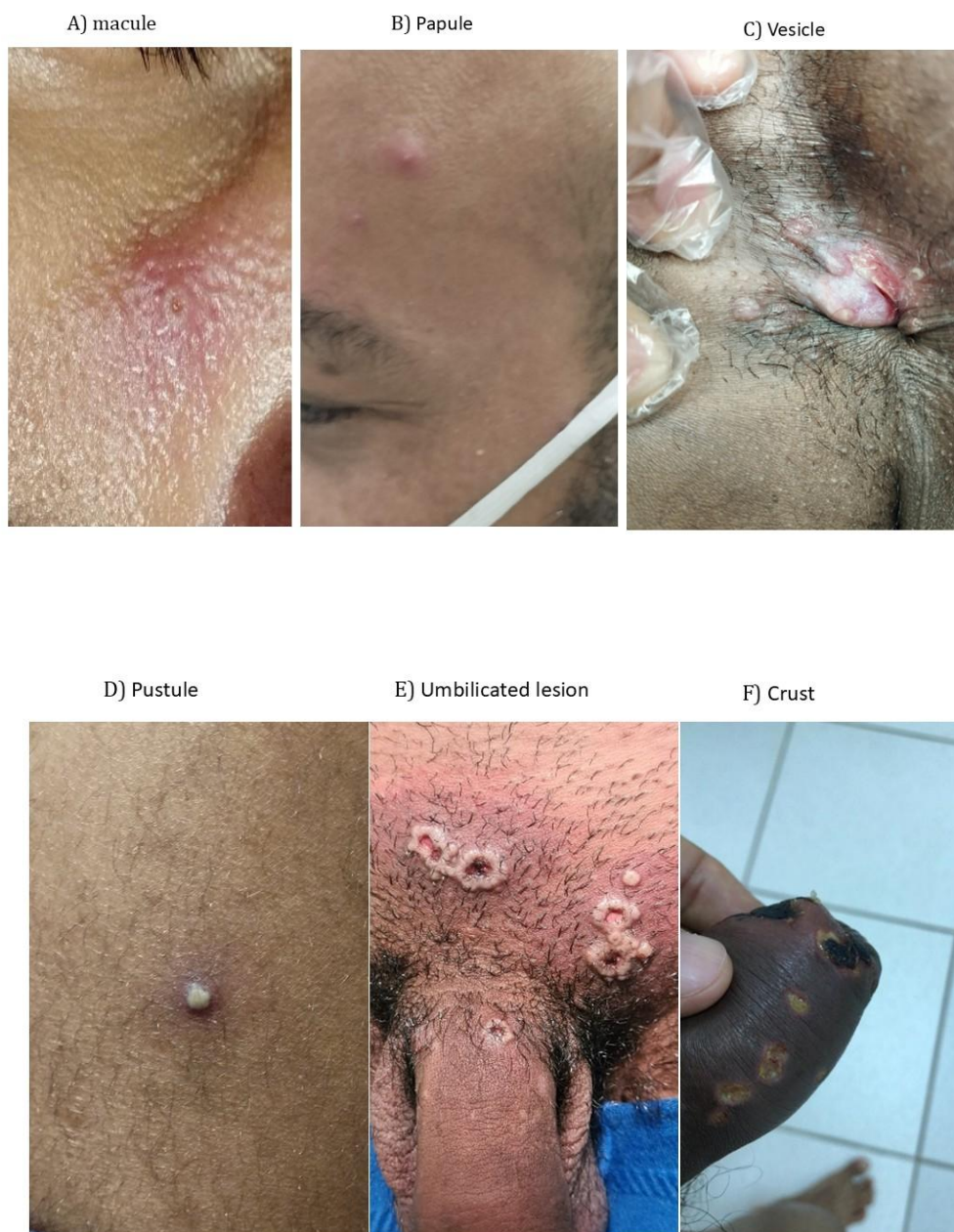Clinical manifestations generally develop within 5 to 21 days after infection (incubation period). The infection is usually mild to moderate in nature and can be divided into two periods: (Figure 6)

**Invasion/Prodromal Period (0–5 days):** Clinical manifestations include fever, intense headache, lymphadenopathy (swollen lymph nodes), back pain, myalgia (muscle aches), and intense asthenia (lack of energy).<sup>42</sup>

**Rash Period (within 1–3 days after the onset of fever):** The skin rash appears in various stages over a period of 10 days, progressing through the following stages: maculopapular (flat-based lesions), vesicles (small fluid-filled blisters), pustules (pus-filled rash), and scabs (dry blisters). (Figure 7) Lesions quantitatively range from 10 to 150 in number,<sup>43</sup> with cutaneous manifestations described as papules, vesicles, pustules, ulcers, dry lesions (scabs), rashes, and/or nodules in different locations such as the face, genitals, and/or diffused,<sup>44</sup> which may or may not be associated with pruritus (itching) and/or swelling, and primarily pain.<sup>42,45,46,47</sup> (Figure 8)

The pain associated with the lesions can be intense, requiring careful assessment of severity for appropriate clinical management. Recent cases have shown a predominance of lesions in the genital and anal regions, with mucous membrane involvement, including oral, rectal, and urethral sites. Specific complications in penile lesions may progress to paraphimosis.<sup>48,49,50</sup> Global data indicates that up to 10% of infected individuals with mpox require hospitalization; although the majority of cases show spontaneous resolution, hospitalization rates vary depending on access to healthcare services, population profile, and disease control strategies. Progression to severe forms, including risk of death, may be associated with factors such as the route of transmission, patient immunosuppression, and the quantity of virus inoculated at the time of transmission.<sup>51</sup>

Figure 7: Evolution of lesions in patients with confirmed mpox diagnosis.



Source: Image Archive of patients treated in the STD Sector-UFF 2022–2024

Text: Although mpox presents a distinct clinical picture, it can overlap with other infections, requiring an accurate and careful differential diagnosis. (Table 1). We must also consider other infectious causes (disseminated gonococcemia) and non-infectious causes (eosinophilic folliculitis, pustular psoriasis, acute febrile neutrophilic dermatosis (Sweet's syndrome)).

Table 1: Differential diagnosis of mpox with the main diseases presenting pustulovesicular manifestations.

Pathology	Similarities	Differences	Incubation Period
<b>Molluscum Contagiosum</b>	Mpox can present deep, umbilicated pseudopustules. Both can affect the trunk, limbs, groin, and genitals. Transmission through intimate contact can be similar.	Does not present a flu-like prodrome; a more chronic course. In immunosuppressed individuals, rapid and diffuse progression increases clinical overlap.	Variable. Spontaneous resolution in 6-12 months.
<b>Herpesvirus</b>	In the vesicular stage, mpox can be confused with herpesvirus infections, such as herpes simplex virus (HSV) and varicella-zoster virus (VZV). Lesions progress to erosions and ulcerations; firm pseudopustules.	Previous history of primary HSV infection: prodrome and rash at the inoculation site with tender lymphadenopathy. Rash evolution: lesions progress to erosions and ulcerations.	1 to 26 days (average 7 days) after contagion.
<b>Chickenpox (Varicella)</b>	Mpox affects children under 10 years old and unvaccinated adults. It can affect mucous membranes and lead to swollen lymph nodes.	Fever, headache, asthenia, irritability, and a <b>cranio-caudal, pruritic rash</b> with reddish spots that evolve into vesicles, pustules, and scabs, <b>typically showing lesions at different stages of evolution concomitantly.</b>	Incubation period < 24hours (on average two weeks).
<b>Hand-Foot-and-Mouth Disease (HFMD)</b>	Presence of vesicles on the oral mucosa; lesions on the hands and feet, in addition to the anogenital region.	More common in children under 10 years of age. Vesicles are generally confined to the oral mucosa with small lesions on the hands and feet.	Lasts only a few days if there are no complications.

Source: Adapted by the author <sup>1,30,34,52</sup>

Table 2: Differential diagnosis of mpox with main STIs presenting ulcerative and pustular lesions.

Pathology	Similarities	Differences	Incubation Period
Syphilis <sup>1,52</sup>	Mpox lesions can mimic the hard chancre of syphilis (painless ulcer at the inoculation site that progresses to a 2 cm. ulcer with raised, indurated borders). May appear in the perioral area, oropharynx, and anogenital region.	Rarely progresses to a scab; generally a single lesion with indurated borders (hard edges).	Incubation Period: 21 to 30 days (range 10 to 90 days).
Chancroid <sup>52</sup>	Mpox presents a superficial, non-tender pustule and may present with lymphadenopathy.	Deep, painful purulent ulcer with inguinal adenitis (bubo formation).	3 to 5 days, possibly reaching 14 days.

Source: STD Atlas & Differential Diagnosis MRLP 2015 <sup>1,52</sup>

The most common neurological symptoms may begin with prodromal signs, such as headaches, generally generalized or frontal, affecting the majority of patients. Additionally, neuralgia and mood disorders may occur,<sup>53</sup> as well as a series of severe viral infections like Guillain-Barré syndrome, transverse myelitis, and acute disseminated encephalomyelitis (ADEM), which can lead to severe complications, including death. Reports also indicate that conjunctivitis and corneal lesions can result in scarring and even vision loss. In rare cases, encephalitis with seizures may occur.<sup>53,54,55,56</sup> To investigate these complications, it is essential to collect biological samples, including cerebrospinal fluid (CSF), for viral and immunological studies.

## OBJECTIVE

To describe the sociodemographic, behavioral, clinical, and laboratory characteristics of a case series of suspected and confirmed mpox cases attended at the STI Sector / Niterói RJ - Brazil.

## METHODS

**Ethical Aspects:** The project was submitted to the Research Ethics Committee, in accordance with Resolution 466/2012 of the National Health Council, under number (CAAE No. 56591822.9.0000.5243).

**Design, Study Location, and Period:** This is a prospective and observational cohort study of a case series of suspected and confirmed mpox cases attended at an STD/STI clinic at UFF Niterói – Brazil.

All patients treated with suspected mpox from June 2022 to March 2024, whose final case definition was established up to April 30, 2024, at the STD Sector/UFF – Niterói- RJ - Brazil, were included. This is the sole care and reference center for Sexually Transmitted Diseases (STD/STI) of the Department of Microbiology and Parasitology (MIP) of the Biomedical Institute (CMB), created in October 1988 under the coordination of Prof. Mauro Romero Leal Passos.

**Sample, Inclusion, and Exclusion Criteria:** The present study included all suspected cases that were classified as confirmed or probable, according to the case definition criteria established by the Ministry of Health on August 5, 2022,<sup>57</sup> who presented with a sudden onset of lesion on the oropharyngeal mucosa and/or acute skin rash on the extremities, genital, anal region, and/or proctitis and/or penile edema, whether or not associated with other signs and symptoms. Among the suspected cases, those who had a positive or detectable laboratory result for the MPX virus by molecular diagnosis (Real-Time PCR) were considered confirmed. Cases with a negative or non-detectable result were excluded (Figure 8).

A suspected case is considered when: the individual, of any age, presents with sudden onset of a lesion on the mucous membranes and/or acute rash suggestive of monkeypox, single or multiple, in any part of the body (including the genital/perianal, oral region) and/or proctitis (e.g., anorectal pain, bleeding), and/or penile edema, which may be associated with other signs and symptoms.<sup>57</sup>

A suspected case is defined by the sudden presence of lesions on mucous membranes and/or an acute rash suggestive of mpox, isolated or multiple, in any region of the body, including genital, perianal, or oral areas, potentially associated with proctitis or penile edema.

A probable case includes the criteria of the suspected case plus one or more epidemiological factors related to close and prolonged exposure, direct physical contact, or contact with materials contaminated by a person with mpox, or occupational exposure without adequate use of PPE, without conclusive laboratory confirmation.

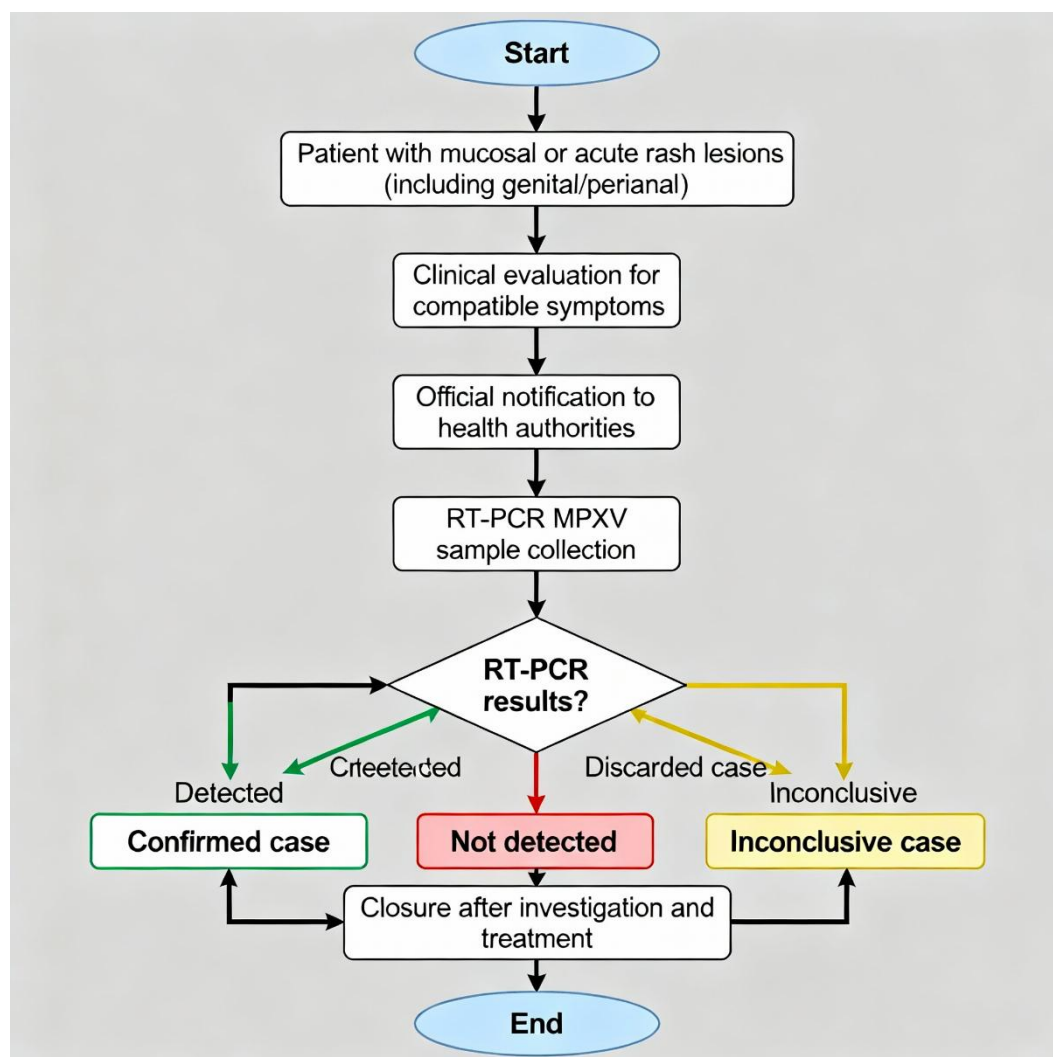
A confirmed case is a suspected case with a positive result for MPXV by molecular diagnosis, such as real-time PCR or sequencing.<sup>57</sup>

MPXV RT-PCR tests were offered to all patients with suspected infection, in addition to the Seegene Allplex™ Genital Ulcer Assay panel for the simultaneous detection of 7 genital ulcer-causing pathogens using real-time PCR Cytomegalovirus (CMV) *Haemophilus ducreyi* (HD), Herpes Simplex Virus type 1 (HSV1), Herpes Simplex Virus type 2 (HSV2), Lymphogranuloma venereum (LGV), *Treponema pallidum* (TP), Varicella-zoster Virus (VZV), and Internal Control (IC). Rapid tests (TR) for syphilis, HIV, Hepatitis B, and C were also performed according to the algorithm of the Brazilian Ministry of Health.



All patients with suspected mpox were routinely followed up on days 3, 6, 21, and 30, aiming to perform at least two consultations within the first 21 days of evolution, or until the resolution of the skin lesions in cases with longer evolution. At each consultation, signs of complications and clinical manifestations were evaluated, and other sexually transmitted infections (STI) were investigated. Contact tracing was also performed, with instructions for a 21-day isolation period. Communication with patients was carried out mainly via WhatsApp and telephone, in addition to scheduled appointments according to individual needs, including partners. Demographic characteristics such as self-declared race/color, education level, sexual activity and orientation, type of partner, symptoms, comorbidities, lesion characteristics, and clinical case evolution were described.

Figure 8: Flowchart for the management of mpox cases in the STD Sector/UFF.



Source: STD Sector/UFF 2022.

## ANALYSIS OF RESULTS AND STATISTICS

The obtained data were stored in an electronic spreadsheet in the Microsoft Office Excel® 2010 program. Subsequently, analyses were performed using the

Jamovi software version 2.3.<sup>28,58,59</sup> with the data entered by the author in the Microsoft Excel software. These analyses were performed using the chi-squared test, with a 95% confidence interval, to verify the association of data between independent samples. The results were described and presented in tables.

From the first suspected case, attended on July 14th up to December 30th, 2022, we attended a total of 28 patients with suspected mpox infection who sought medical care at the STD/UFF Niterói – RJ - Brazil Sector. Of these patients, 18 (64.28%) were confirmed (positive) cases.

In 2023, we attended only one suspected case, while in January 2024, we had 4 patients with suspected mpox, with two (50%) patients discarded (negative) and two (50%) cases confirmed by RT-PCR. Thus, our sample was composed of 33 (100%) suspected cases for mpox, with 20 (60.6%) positive cases confirmed by molecular biology (RT-PCR) and 13 (39.4%) unconfirmed cases that were considered discarded or negative cases.

Data updated as of August 13, 2024, available on the panel of the Center for Strategic Information and Health Surveillance Response (CIEVS), of the State Health Secretariat (SES), show that the metropolitan region II (Niterói, São Gonçalo, Maricá, and Itaboraí) has 9.75%, or 161 confirmed cases; thus, our cases represent 12.42%.

Out of 33 people with suspected mpox, 20 (60.6%) were confirmed, compared to unconfirmed cases (18.2%). The majority of confirmed cases were of the male sex assigned at birth (81.80% vs. 18.2%);  $p=0.015$ , indicating that this difference is not random, suggesting that the male sex was an associated factor for diagnostic confirmation in the studied population. The median age for confirmed cases was 36 (IQR: 15), and for unconfirmed or discarded cases it was 29 years (IQR: 9). Among the confirmed cases, ages 21 to 39 were cisgender men, compared to ages 21 to 30 for unconfirmed cases (70% vs. 69.2%),  $p=0.278$ . This means that differences in age groups could be due to chance, and age alone does not appear to be a determining factor for diagnostic confirmation. The race/color "black" (55% vs. 45%),  $p=0.449$ , showed no statistically significant difference in distribution between the groups. Residents of São Gonçalo (50% vs. 30.8%),  $p=0.335$ , and those with a complete higher education degree (45% vs. 30.8%),  $p=0.429$  (Table 1), were not statistically different between the groups. The cisgender male gender (95% Vs 61.54%) has strong statistical significance  $p=0.015$ . Sexual orientation MSM (Men who have Sex with Men) (80% Vs 53.84%),  $p=0.508$ , and having a non-exclusive steady partner (50% vs. 7.69%).

The type of partnership was not found to be a statistically significant factor  $p=0.233$ , for diagnostic confirmation, along with good knowledge of STIs, and attitudes and practices of prevention (75% vs. 46.15%). There is no statistically significant difference in the perception of sexual education between the groups  $p=0.204$ , nor is there a difference regarding who uses condoms. The vast majority

of patients in both groups report occasional use (80% vs. 61.54%)  $p=0.500$  (Table 2). These patients were referred by a health professional (70% vs. 61.54%); this category shows statistical significance  $p<0.041$ , and syphilis is the main differential diagnosis (30% vs. 30.77%)  $p=0.415$  (Table 3). The analysis performed concerns the declared municipalities of residence, in order to support actions to break the chain of transmission, such as contact tracing, and do not reflect the likely place of infection.

Table 1: Sociodemographic characteristics of the studied population according to mpox diagnosis at the first medical evaluation (N=33).

Characteristic	Confirmed Cases (n=20;60.6%) n/ total (%)	Unconfirmed Cases (n=13;39,4%) n/total(%)	P value	
<b>Sex at Birth</b>				
Male	19/20 (95%)	8/13 (61,5%)	0.015	
Female	1/20 (5%)	5/13 (38,5%)		
<b>Age (Years)</b>				
Median (IQR)	36	29	0.278	
<20	0/20 (0,0 %)	0/13 (0,0%)		
21-30	7/20 (35 %)	9/13 (69,2%)		
31-40	7/20 (35%)	2/13 (15,38%)		
41- 48	4/20 (20%)	1/13 (7,7 %)		
> 49	2/20 (10%)	1/13 (7,7%)		
<b>Race/Color (Self-reported)</b>				
Black	3/20 (15%)	5/13 (38,5%)	0.449	
Brown (Mixed)	8/20 (40%)	1/13 (7,7%)		
White	9/20 (45%)	7/13 (53,8%)		
Indigenous	0/20 (0,0)	0/13 (0,0)		
<b>Education Level</b>				
<b>Illiterate</b>	1/20 (5%).	0/13 (0,0%)	0.429	
Incomplete Secondary School	1/20 (5%)	1/13 (7,7%)		
Complete Secondary School	6/20 (30%)	2/13 (15,4%)		
Incomplete Higher Education	9/20 (45%)	4/13 (30,8%)		
<b>Complete Higher Education</b>	3/20 (15%)	6/13 (46,2%)	0.335	
<b>Place of Residence</b>				
Niteroi	9/20 (45%)	9/13 (69,2%)		
Sao gonçalo	10/20 (50%)	4/13 (30,8%)		
Marica	1/20 (5%)	0/13 (0,0%)		
<b>History of Travel</b>				
Other State (within Brazil)	2/20 (10%)	0/13 (0,0%)		
Foreign Country	0/20 (0,0)	0/13 (0,0%)		
<b>Vaccinated Against Smallpox *</b>				
Yes	2/20 (10%)	1/13 (7,7%)		

No	18/20 (90%)	0/13 (0,0%)
----	-------------	-------------

\*Individuals born before 1975

Source: Patient records from the STD/UFF Sector 2022-2024

Table 2: Behavioral Characteristics of the Studied Population According to mpox Diagnosis at the First Medical Evaluation (N=33)

Characteristic	Confirmed Cases (n=20; 60.6%) n/total (%)	Unconfirmed Cases (n=13; 39.4%) n/total (%)	p-value
<b>Gender</b>			
Cisgender Man	19/20 (95%)	8/13 (61,54%)	0.015
Cisgender Woman	1/20 (5,0 %)	5/13 (38,46%)	
Others	0/20 (0,0%)	0/13 (0,0%)	
<b>Sexual Orientation</b>			
Homosexual	12/20(60,0%)	6/13 (46,15%)	0.508
Bisexual	4/20 (20,0 %)	1/13 (7.69%)	
Heterosexual	4/20 (20,0%)	6/13 (46,15%)	
<b>Type of Partnership</b>			
Exclusive Steady	6/20 (30%)	6/13 (46,15%)	0.233
Non-Exclusive Steady	10/20 (50%)	1/13 (7.69%)	
Multiple Partners	4/20 (20%)	4/13 (30,77%)	
<b>Sexual Education/Knowledge</b>			
Good	15/20 (75%)	6/13 (46,15%)	0.204
Little	3/20 (15%)	3/13 (23,08%)	
None	2/20 (10%)	4/13 (30,77%)	
<b>Condom Use</b>			
Always	1/20 (5%)	1/13 (7,69%)	0.500
Sometimes	16/20 (80%)	8/13 (61,54%)	
Never	3/20 (15%)	4/13 (30,77%)	

Source: Patient records from the STD/UFF Sector 2022-2024.

\*c) Gays and other MSM (Men who have Sex with Men) were defined as individuals of the male sex at birth who reported having sexual relations only with men or having sexual relations with both men and women.

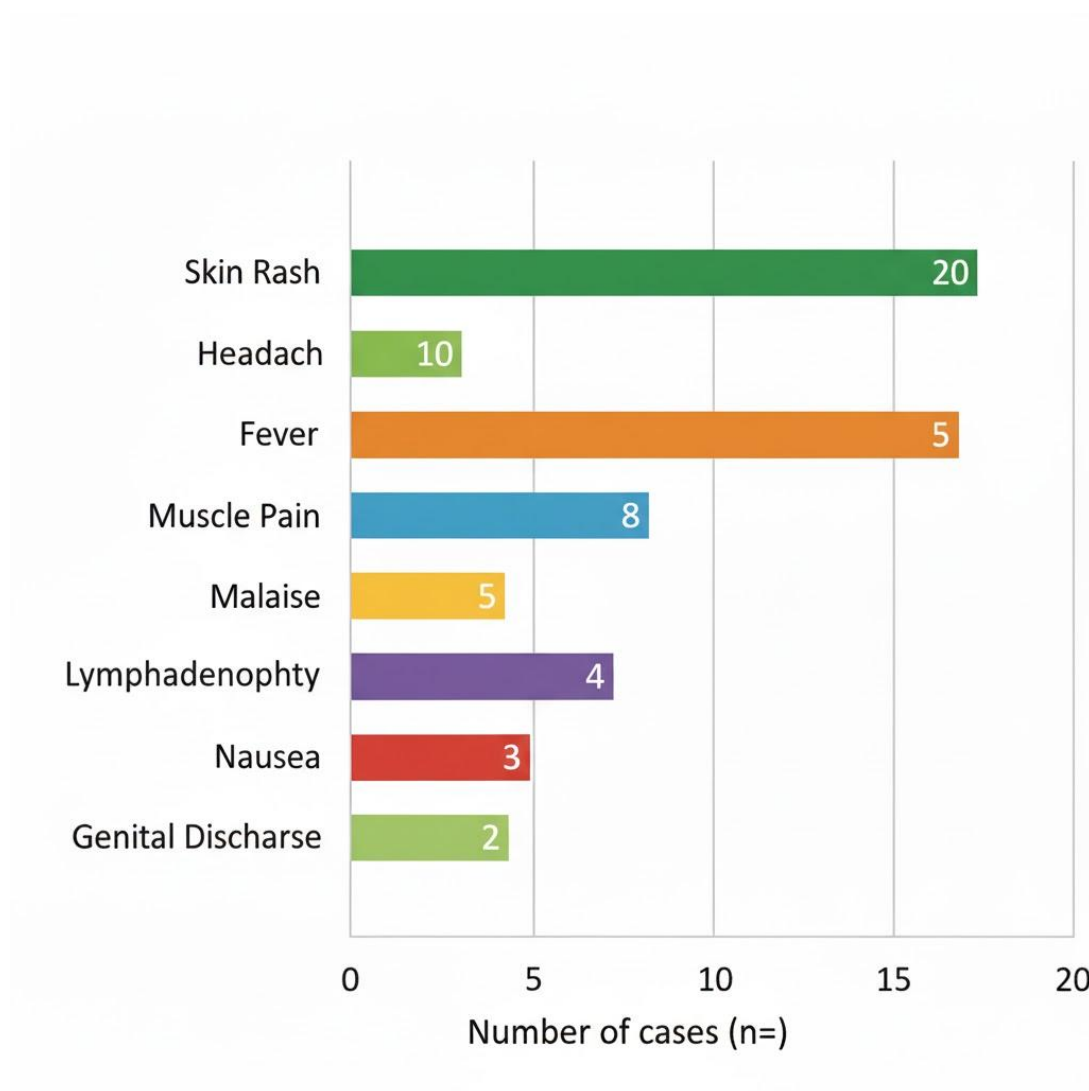
Table 3: Type of Referral and Referral Diagnosis of the Studied Population According to mpox Diagnosis at the First Medical Evaluation (N=33)

Characteristic	Confirmed Cases (n= 20; 60,6%) n/total (%)	Unconfirmed Cases (n=13;39,4%) n/total (%)	<i>p-value</i>
Referred by:			
UBS/Family Doctor	10/20 (50%)	8/13 (61,54%)	0.041
Private Doctor	2/20 (10%)	0/13 (0,0%)	
UBS Nurse	2/20 (10 %)	0/13 (0,0%)	
Partner	5/20 (25%)	0/13 (0,0%)	
Friend	1/20 (5%)	2/13 (15,38%)	
Spontaneous Search	0/20 (0,0%)	3/13 (23,08%)	
Referral Diagnosis			
Mpox	7/20 (35%)	4/13 (30,77%)	0.415
Syphilis	6/20 (30%)	4/13 (30,77%)	
HPV	3/20 (15%)	2/13 (15,38%)	
Herpes	4/20 (20%)	2/13 (15,38%)	
No Diagnosis	0/20 (0,0%)	3/13 (23,08%)	
Partner Examined			
Yes	13/20 (65%)	0/13 (0,0%)	< 0.001
No	7/20 (35%)	13/13 (100%)	

Source: Patient records from the STD/UFF Sector 2022-2024

Among the most prevalent systemic signs and symptoms of confirmed and discarded mpox cases, the most frequent were: skin rash (n=20; 100%), fever (n=10; 50%), headache (n=8; 40%), followed by muscle pain (n=5; 25%), malaise (n=4; 20%), lymphadenopathy (n=3; 15%), nausea (n=2; 10%), and genital discharge (n=2; 10%) (Figure 9).

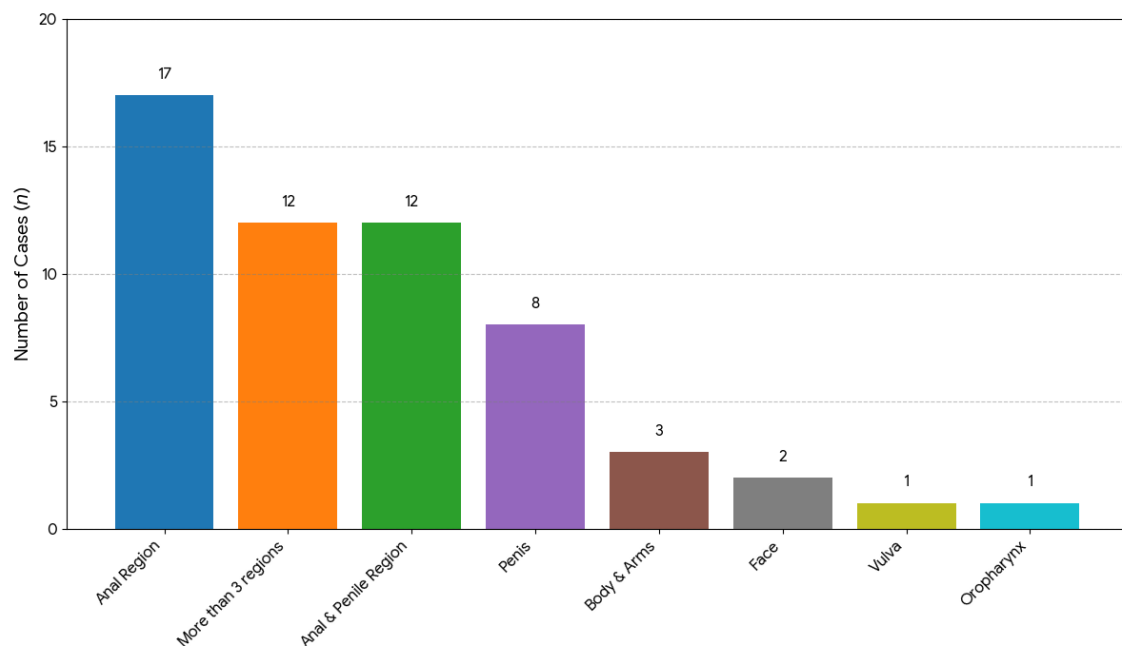
Figure 13: Relative frequency of reported signs and symptoms among confirmed mpox cases, from July 14, 2022, to April 30, 2024 (n=20)



Source: Patient records from the STD/UFF Sector 2022-2024.

Regarding the characteristics of the lesions, confirmed cases presented more genital lesions (60% Vs. 39.8%) and anal lesions (85% Vs. 30.8%) of the patients. (n=12; 60%) presented lesions in the anal region and on the penis simultaneously. (n=12; 60%) presented lesions in three regions of the body, including other body parts such as the face, chest, arms, oropharynx, and one patient presented lesions on the vulva (n=7; 30%) (Figure 14).

Figure 14: Location of lesions in patients with confirmed mpox diagnosis from July 14, 2022, to April 30, 2024 (n=20)



Source: Patient records from the STD/UFF Sector 2022-2024.

Of the positive cases (13/20; 65%) in this category, the p-value is extremely low and therefore highly significant ( $p < 0.001$ ), indicating that the sexual partnership was examined at DST-UFF. Of these partners, 38.46% were mpox positive. We had no severe cases and no hospitalization was necessary.

Finally, it was observed that most patients were not immunosuppressed. However, it is noteworthy that, among confirmed cases, 45% were people living with HIV (PLHIV). 33.33% had an active sexually transmitted infection (STI), the most prevalent being syphilis in male patients, the majority of whom were white and older (31 to 48 years old). All of them were men who have sex with men (MSM) and presented with more anal lesions. PrEP (Pre-Exposure Prophylaxis) use was (27% vs. 23%); PEP (Post-Exposure Prophylaxis) use was (9%).

## DISCUSSION

The analysis of the mpox outbreak in Niterói (RJ, Brazil) contributes to broadening the understanding of the disease's epidemiological behavior in the Brazilian context and reinforces nationally observed trends, such as the concentration of cases among young male individuals, especially cisgender men with homo/bisexual practices. This is consistent with current records from the Ministry of Health and international literature. Although the number of notifications has decreased since the end of 2022, the impact of community transmission, particularly through intimate and sexual contact, remains relevant and highlights the emergence of new chains of infection.<sup>65</sup>

The present study underscores the importance of accurate differential diagnosis given the clinical overlap with other sexually transmitted infections (STIs), such as syphilis and genital herpes. The use of advanced laboratory methods, including RT-PCR, electron microscopy, and molecular STI panels, proved essential for the early identification and correct management of cases. It also contributed to the monitoring of concomitant infections, such as HIV, a frequently observed condition, with patients maintaining adequate immunological control. The clinical evolution observed in this study was predominantly self-limiting, with no record of severe complications or need for hospitalization, corroborating other recent reports and epidemiological bulletins.<sup>66,67</sup>

The behavioral profile of the participants revealed risky sexual practices, such as non-exclusive partnerships and irregular condom use, and variable access to preventive measures. These aspects reinforce the need for educational strategies and expanded access to health services. The predominance of referrals by professionals and social networks highlights the role of these structures in the outbreak response but also points to informational gaps among the general population.<sup>68</sup>

The clinical evolution observed in this study was predominantly self-limiting, with no record of severe complications or need for hospitalization, corroborating other recent reports and epidemiological bulletins.<sup>69</sup> However, the initial diagnostic limitation and the predominance of male participants restrict the extrapolation of the results to women and other gender identities, indicating the urgency of more inclusive research that addresses diverse demographic profiles.<sup>70</sup>

Another relevant aspect consists of the decline in collective immunity following the discontinuation of smallpox vaccination, a factor that may have favored the resurgence of mpox in susceptible populations. Given this scenario, it is essential to maintain investment in epidemiological surveillance, team training, and the enhancement of service infrastructure to ensure a timely and efficient response in future emergencies.<sup>71</sup>

Furthermore, the persistent challenge of stigma linked to mpox and the sexual orientation of patients is highlighted, which demands continuous efforts to promote inclusive communication, combat discrimination, and ensure equity in access to care.<sup>72</sup> The findings of this study support the development of segmented public policies, in addition to stimulating research on transmission dynamics, the effectiveness of preventive actions, and the social impacts resulting from mpox in the national scenario.

## **STRENGTHS**

This study was conducted in a reference clinic for sexually transmitted infections (STIs), which ensures diagnostic accuracy through the use of robust laboratory methods, such as RT-PCR and EM (Electron Microscopy) for the Monkeypox



virus (MPXV). Additionally, the research included a comprehensive laboratory panel for the differential diagnosis of other STIs, strengthening the precision of the data obtained. The detailed analysis of sociodemographic, clinical, and behavioral variables of confirmed cases provided a comprehensive overview of the local mpox outbreak in Niterói, Rio de Janeiro State, Brazil, contributing to the advancement of regional epidemiological knowledge. The longitudinal follow-up of patients enabled the observation of clinical evolution, highlighting the absence of severe complications and characterizing the disease's self-limited behavior in this context. Due to the welcoming nature of the service, the rate of sexual partner examination was high.

## **LIMITATIONS**

Among the main limitations of the study, the relatively small sample size stands out, which may compromise the generalization of findings to other populations or regions. The limitation of diagnostic capacity, especially at the beginning of the outbreak, may have resulted in underreporting, affecting the representativeness of the analyzed data. The retrospective and observational design is subject to selection bias and possible information gaps inherent to this type of investigation. The concentration of male participants restricts the extrapolation of results to women and other gender identities, highlighting the need for more inclusive research. Finally, difficulties in mapping transmission chains limited the scope of the analysis regarding the epidemiological dynamics of the outbreak.

## **CONCLUSION**

Updated data as of August 13, 2024, contained within the panel of the Center for Strategic Information and Health Surveillance Response (CIEVS), from the State Department of Health (SES) during the study period, indicated that the Metropolitan Region II (Niterói, São Gonçalo, Maricá, and Itaboraí) accounted for 9.75% of the 161 confirmed cases, thus our cases represented 12.42%.

The vast majority of patients with a positive mpox diagnosis were male assigned at birth, cisgender men, and came from São Gonçalo. Most were Black, had a good educational level, engaged in same-sex relations (MSM), were young with non-exclusive sexual partners, had good knowledge about STIs, and used condoms occasionally, with some having traveled to other states. The most common symptoms were pain, fever, and the presence of proctitis, and the large majority presented with perianal lesions.

None of the patients with a positive mpox diagnosis required hospitalization, and no deaths were recorded. Most were referred by a public health professional, with syphilis and herpes being the main diagnoses among the referrals. Most partners were called in and examined.

Comparing mpox-positive patients living with HIV versus those who were not, the HIV-positive individuals were older, presented with an undetectable viral load and

a CD4 count greater than 500 cells/mm<sup>3</sup>, were white residents of São Gonçalo, and most had completed higher education. The comorbidity with syphilis was high.

### **Author Contributions**

WNCA: Study conception, data collection and curation, manuscript drafting, critical review of intellectual content.

ICNPP: Statistical analysis, data collection, organization of tables/figures, methodology review, coordination in laboratory analysis, contribution to molecular diagnosis, clinical discussion.

CCCSP: Laboratory testing, interpretation of laboratory results, critical review of the manuscript.

CSB: Literature review, text revision, image processing

KR: Image supervision (electron microscopy ), organization and iconographic description.

MSL: Statistical analysis, text review.

HBA: Support in participant recruitment, clinical follow-up and monitoring, clinical material collection, support in clinical epidemiological interpretation.

IAS: Patient screening, clinical follow-up, clinical material collection, obtaining consent, follow-up monitoring.

CTMB: Coordination in laboratory analysis, contribution to molecular diagnosis.

JJC: Image supervision (electron microscopy), organization and iconographic description.

AGAFG: Bibliographic research, final review of references and Vancouver norms.

LGCC: Graph elaboration, final review of references and Vancouver norms.

ACCC: Table structuring, final review of references and Vancouver norms.

MRLP: Medical care for all patients, clinical material collection, academic guidance, authorized photographs, project conception, final review of the manuscript, and approval of the submitted version.

### **Funding**

The authors declare no financial support. All patients were treated within the Sistema Único de Saúde (SUS) public healthcare network.

### **Conflict of Interest**

The authors declare no conflicts of interest.

## References

1. Petersen E, Kantele A, Koopmans M, Asogun D, Yinka-Ogunleye A, Ihekweazu C, Zumla A. Human monkeypox: epidemiologic and clinical characteristics, diagnosis, and prevention. *Infect Dis Clin North Am*. 2019 Dec;33(4):1027-43. doi: 10.1016/j.idc.2019.03.001.
2. Bunge EM, Hoet B, Chen L, Lienert F, Weidenthaler H, Baer LR, et al. The changing epidemiology of human monkeypox—a potential threat? A systematic review. *PLoS Negl Trop Dis*. 2022 Feb;16(2):e0010141. doi: 10.1371/journal.pntd.0010141.
3. Dhawan M, Bin Emran T, Isla F. O ressurgimento de casos de monkeypox: razões, avaliação de ameaças e possível preventivo medidas. *Viagem Med Infect Dis*. 2022;49:102367.
4. World Health Organization. Laboratory biosafety guidance related to monkeypox virus. 2022. Available from: <https://www.who.int/>
5. WHO. Surto de mpox em 2022: tendências globais. 2023. Available from: [https://worldhealthorg.shinyapps.io/mpx\\_global/](https://worldhealthorg.shinyapps.io/mpx_global/) [accessed 14 Jan 2024].
6. Valle CG. Néstor Perlongher e o dispositivo da aids. *Cadernos Pagu*. 2022;66:e226604. doi:10.1590/1809-44492022000226004.
7. Foucault M. *Histoire de la Sexualité* (vol. II et III). Paris: Gallimard; 1984.
8. OPAS/OMS—Brasil. Estudo multicêntrico de análise clínico-epidemiológica da mpox no Brasil: contribuições ao Sistema Único de Saúde e à Plataforma Clínica Global da OMS. 2023.
9. Faye O, Pratt CB, Faye M, et al. Genomic characterisation of human monkeypox virus in Nigeria. *Lancet Infect Dis*. 2018 Mar;18(3):246. doi: 10.1016/S1473-3099(18)30043-4.
10. Shchelkunov SN. Um perigo crescente de infecções zoonóticas por ortopoxvírus. *PLoS Pathog*. 2013 Dec;9(12):e1003756. doi: 10.1371/journal.ppat.1003756.
11. Espírito-Santo M, Silva F, Souza C. Poxvírus: características genômicas e estrutura viral. *Revista de Virologia*. 2023;29(1):45-56.
12. Bayer Garner I. Vírus da varíola dos macacos: achados histológicos, imuno-histoquímicos e microscópicos eletrônicos. *J Cutan Pathol*. 2005;32:28-34.

13. International Committee on Taxonomy of Viruses. ICTV taxonomy. 2022. Available from: <https://ictv.global/report/chapter/poxviridae/poxviridae> [accessed 20 Jun 2024].
14. Knipe DM, Howley PM, editors. *Fields Virology*. 6th ed. Philadelphia: Lippincott Williams & Wilkins; 2013.
15. Karagoz A, Tombuloglu H, Alsaeed M, Tombuloglu G, AlRubaish AA, Mahmoud A, Smajlović S, Ćordić S, Rabaan AA, Alsuhaimi E. Monkeypox (mpox) virus: Classification, origin, transmission, genome organization, antiviral drugs, and molecular diagnosis. *Journal of Infection and Public Health*. 2023 Apr;16(4):531-541. doi: 10.1016/j.jiph.2023.02.003. Epub 2023 Feb 9. PMID: 36801633.
16. Nawaz S, Fatima A. Monkeypox viruses: resurgence of global threat to mankind. *Int J Microbiol Res*. 2022;14(12):103-105. doi: 10.26855/ijmr.2022.12.003.
17. Hughes AL, Irausquin S, Friedman R. The evolutionary biology of poxviruses. *Infect Genet Evol*. 2010 Jan;10(1):50-9.
18. Mackett M, Archard LC. Conservation and variation in Orthopoxvirus genome structure. *J Gen Virol*. 1979 Dec;45(3):683-701. doi:10.1099/0022-1317-45-3-683.
19. Buller RM, Palumbo GJ. Poxvirus pathogenesis. *Microbiol Rev*. 1991 Mar;55(1):80-122.
20. Smith GL, Law M. The exit of vaccinia virus from infected cells. *Virus Res*. 2004 Feb;106(2):189-97.
21. Shchelkunov SN, et al. Analysis of the monkeypox virus genome. *Virology*. 2002 Aug;297(1):172-94.
22. Vandenbogaert M, et al. Nanopore sequencing of a monkeypox virus strain isolated from a pustular lesion in the Central African Republic. *Sci Rep*. 2022 Jul;12(1):10768.
23. Hendrickson RC, Wang C, Hatcher EL, Lefkowitz EJ. Orthopoxvirus genome evolution: the role of gene loss. *Viruses*. 2010 Sep;2(9):1933-67.
24. Kugelman JR, Johnston SC, Mulembakani PM, Kisalu N, Lee MS, Koroleva G, et al. Genomic variability of monkeypox virus among humans, Democratic Republic of the Congo. *Emerg Infect Dis*. 2014 Feb;20(2):232-9. doi: 10.3201/eid2002.130118.
25. Alakunle E, Okeke MI. Vírus Monkeypox: um patógeno zoonótico negligenciado se espalha globalmente. *Nat Rev Microbiol*. 2022 Jul;20(9):507-8.

26. Chen N, Li G, Liszewski MK, Atkinson JP, Jahrling PB, Feng Z, et al. Differences in virulence between West African and Congo Basin monkeypox virus isolates. *Virology*. 2005 Oct;340(1):46-63.
27. Likos AM, Sammons SA, Olson VA, Frace AM, Li Y, Olsen-Rasmussen M, et al. The tale of two clades: monkeypox viruses. *J Gen Virol*. 2005 Nov;86(Pt 5):2661-72.
28. Hutson CL, Abel JA, Carroll DS, Olson VA, Braden ZH, et al. Comparison of West African and Congo Basin monkeypox viruses in BALB/c and C57BL/6 mice. *PLoS One*. 2010 Jan;5(1):e8912. doi: 10.1371/journal.pone.0008912.
29. Sah R, Abdelaal A, Reda A, Katamesh BE, Manirambona E, Abdelmonem H, et al. Monkeypox and possible sexual transmission: where are we now with its evidence? *Pathogens*. 2022 Aug;11(8):924.
30. Organização Pan-Americana da Saúde. Casos de varíola dos macacos - Região das Américas. Washington, D.C.: OPAS; 2024 [cited 2024 Jul 25]. Available from: <https://shiny.paho-phe.org/mpox/>
31. Kaler J, Hussain A, Flores G, Kheiri S, Desrosiers D. Monkeypox: a comprehensive review of transmission, pathogenesis, and manifestation. *Cureus*. 2022 Jul;14(7).
32. Moss B. Poxvirus entry and membrane fusion. *Virology*. 2006 Jan 5;344(1):48-54. doi: 10.1016/j.virol.2005.09.037.
33. Vanhamel J, Laisnez V, Liesenborghs L, et al. Understanding sexual transmission dynamics and transmission contexts of monkeypox virus: a mixed methods study of the early outbreak in Belgium (May–June 2022). *Sex Transm Infect*. 2023 Apr;99(4):330-6.
34. OMS. Genebra; 2024. Available in Spanish from: <https://www.who.int/es/news-room/fact-sheets/detail/monkeypox> [accessed 18 Ag.2024].
35. Meaney-Delman DM, Galang RR, Petersen BW, Jamieson DJ. A primer on monkeypox virus for obstetrician-gynecologists: diagnosis, prevention, and treatment. *Obstet Gynecol*. [Internet]. Available from: <https://www.cdc.gov/poxvirus/monkeypox/> [accessed 20 Apr 2024].
36. Mbala PC, Huggins JW, Reynolds MG, et al. Vigilance, case investigation and contact tracing for monkeypox: Interim guidance. World Health Organization; 2022 Aug 25.
37. Kreutz LC, Rezende MA, Maté YA. Varíola dos macacos (Monkeypox virus - Poxviridae): uma breve revisão. *Ars Veterinaria*. 2022;38(3):111-115.

38. Reynolds MG, Yorita KL, Kuehnert MJ, Davidson WB, Huhn GD, Holman RC, et al. Clinical manifestations of human monkeypox influenced by route of infection. *J Infect Dis.* 2006;194(6):773-80. doi:10.1086/505880.
39. Vaughan A, Arons E, Astbury J, Balasegaram S, Beadsworth M, Beck CR, et al. Two cases of monkeypox imported to the United Kingdom, September 2018. *Euro Surveill.* 2018 Sep;23(38):1800509.
40. Pacheco FIL, Souza LER, Nascimento LV, et al. Características epidemiológicas e clínicas dos casos de monkeypox no Brasil: uma revisão. *Rev Saude Publica.* 2022;56(4):[páginas]. Disponível em: <https://www.scielo.br/j/ress/a/8h78V5sVZLKBYRyKjB8XJtG/>
41. McCollum AM, Damon IK. Human monkeypox. *Clin Infect Dis.* 2014 Jul;58(2):260-7.
42. Patel A, Bilinska J, Tam JCH, Da Silva Fontoura D, Mason CY, Daunt A, et al. Clinical features and novel presentations of human monkeypox in a central London centre during the 2022 outbreak: descriptive case series. *BMJ.* 2022 Jun 1;378:e072410.
43. Reynolds MG, et al. Monkeypox re-emergence in Africa: a call to expand the concept and practice of One Health. *Expert Rev Anti Infect Ther.* 2019 Feb;17(2):129-39.
44. Organização Pan-Americana da Saúde. Atualização epidemiológica mpox na Região das Américas, 20 de dezembro de 2024. Washington, D.C.: OPAS; 2024. Disponível em: <https://www.paho.org/sites/default/files/2024-12/2024-dez-20-phe-atualizacao-epi-mpox-pt.pdf> [accessed 06 Feb 2025].
45. Centers for Disease Control and Prevention. Clinical recognition: key characteristics for identifying mpox. 2023. Available from: <https://www.cdc.gov/poxvirus/mpox/clinicians/clinical-recognition.html> [accessed 22 Mar 2024].
46. Yong SEF, Ng OT, Ho ZJM, Mak TM, Marimuthu K, Vasoo S, et al. Imported monkeypox, Singapore. *Emerg Infect Dis.* 2020 Aug;26(8):1826-30. Disponível em: <https://www.paho.org/sites/default/files/2022-09/who-mpx-surveillance-2022-port.pdf>
47. Costello V, Sowash M, Gaur A, Cardis M, Pasieka H, Wortmann G, et al. Imported monkeypox from international traveler, Maryland, USA, 2021. *Emerg Infect Dis.* 2022 May;28(5):1002-5.
48. Van Furth AMT, van der Kuip M, van Els AL, Fievez LC, van Rijckevorsel GG, vanden Ouden A, et al. Paediatric monkeypox patient with unknown source of infection, the Netherlands, June 2022. *Euro Surveill.* 2022 Jul;27(29):2200552.

49. Lopes A, Silva R, Pereira M, et al. Complicações da varíola dos macacos: uma revisão integrativa da literatura. *Saúde Pública*. 2023;3(4):279-285. Disponível em: <https://www.periodicojs.com.br/index.php/hs/article/download/1485/1292/4524>. [accessed 22 Mar 2024].
50. Freitas MA, Gancedo Saber AJ, Milhomem JPL, Ávila JMB, Ramirez AC, Remor AMR, Castro Júnior JWG, Sousa JPS, Roberto AL, Cruz BCD, Menezes CAGP. Abordagens terapêuticas e epidemiológicas na prevenção e controle da mpox: uma revisão atualizada. *Revista FT*. 2022;3(4). Disponível em: <https://revistaft.com.br/abordagens-terapeuticas-e-epidemiologicas-na-prevencao-e-controle-da-mpox-uma-revisao-atualizada/> [accessed 22 Mar 2024].
51. Gomez R, Silva T, Carvalho P, et al. Variantes e impacto epidemiológico da varíola dos macacos: uma revisão atualizada. *Rev Epidemiol Saúde Pública*. 2023;12(2):145-153.
52. Passos MRL. Atlas de DST & Diagnóstico Diferencial. 2nd ed. Rio de Janeiro (RJ): Reverter; 2012.
53. Jezek Z, Szczeniowski M, Paluku KM, Mutombo M. Human monkeypox: clinical features of 282 patients. *J Infect Dis*. 1987 Feb;156(2):293-8.
54. Adler H, Gould S, Hine P, Snell LB, Wong W, Houlihan CF, et al. Clinical features and management of human monkeypox: a retrospective observational study in the UK. *Lancet Infect Dis*. 2022 Aug;22(8):1153-62.
55. Ogoina D, Iroezindu M, James HI, et al. Clinical course and outcome of human monkeypox in Nigeria. *Clin Infect Dis*. 2020 Oct;71(15):e210-14.
56. Sousa AFL, Sousa AR, Fronteira I. Monkeypox: between precision public health and stigma risk. *Rev Bras Enferm*. 2022;75(5):e750501. doi: 10.1590/0034-7167.2022750501.
57. Brasil. Ministério da Saúde. Sala de Situação de Monkeypox (Desativada). 2022. Available from: <https://www.gov.br/saude/pt-br/composicao/svsa/resposta-a-emergencias/sala-de-situacao-desauade/sala-de-situacao-de-monkeypox> [accessed 28 Jun 2023].
58. The jamovi project. jamovi (Version 2.3) [Computer software]. 2022. Available from: <https://www.jamovi.org>
59. R Core Team. R: A language and environment for statistical computing (Version 4.1) [Computer software]. 2021. Available from: <https://cran.r-project.org>
60. Pascom ARP, Souza IN, Krummenauer A, Duarte MMS, Sallas J, Rohlf DB, Pereira GM, Medeiros AC, Miranda AE. Epidemiological and clinical characteristics of monkeypox cases in Brazil in 2022: a cross-sectional study.

Epidemiol Serv Saude. 2022;31(3):e2022851. doi:10.1590/S2237-96222022000300036.

61. Girometti N, et al. Demographic and clinical characteristics of confirmed human monkeypox virus cases in individuals attending a sexual health centre in London, UK: an observational analysis. *Lancet Infect Dis.* 2022 Sep;22(9):1321-8.

62. Silva MST, Coutinho C, Torres TS, Peixoto E, Ismerio R, Lessa F, et al. Ambulatory and hospitalized patients with suspected and confirmed mpox: a Brazilian observational cohort study. *Lancet Reg Health Am.* 2022;17:100406. doi:10.1016/j.lana.2022.100406.

63. Spirito F, Guida A, Caponio VCA, Lo Muzio L. Monkeypox: a new challenge for global health system? *Life (Basel).* 2023 May 25;13(6):1250. doi:10.3390/life13061250.

64. Alvares RM, SOUZA RP, COSTA LT, MARTINS GA, OLIVEIRA TM, et al. Uso de testes laboratoriais para diagnóstico diferencial em surtos de mpox: uma revisão. *Rev Bras Infectol.* 2024;28(2):45-52.

65. Campos FS, oliveira JC. Perfil epidemiológico e comportamental em surto de mpox: desafios e respostas. *J Saúde Pública.* 2023;36(4):300-9.

66. costa LP, santos RM, almeida FC, et al. Transmissão comunitária de mpox no Brasil: análise de tendências recentes. *Epidemiol Serv Saúde.* 2023;31(3):e2022851.

67. Ferreira MA, Lima RS. Necessidade de inclusão de gênero e diversidade em pesquisas sobre mpox. *Ciênc Saúde Coletiva.* 2024;29(1):15-22.

68. Martins AR, pereira LG. Estigma e saúde pública: enfrentando barreiras na resposta a mpox. *Saúde Debate.* 2023;47(130):60-70.

69. Oliveira TF, Souza PH. Impacto da cessação da vacinação contra varíola na reemergência do mpox. *Rev Vigilância Saúde.* 2023;11:101-10.

70. Pereira AL, Barros TC, Lucena MP, et al. Métodos diagnósticos em surtos de mpox e IST concomitantes. *Rev Med Bras.* 2023;40(3):200-7.

71. Santos GV, Andrade FL, Costa VP, et al. Evolução clínica do mpox: análise de dados brasileiros. *Arq Epidemiol.* 2023;15(2):75-82.

72. Silva MJ, Almeida RA, Pimenta DS, et al. Epidemiologia da mpox no Brasil: avanços e desafios. *J Bras Doenças Infect.* 2024;29(1):10-20.



## Corresponding Authors

MD.PhD. Wilma Nancy Campos Arze<sup>1</sup> <https://orcid.org/0000-0002-2620-0620>, Universidade Federal de Integração Latino-Americana UNILA – Foz do Iguaçu (PR), Brasil. E-mails: [wilma.arze@gmail.com](mailto:wilma.arze@gmail.com);

PhD Izabel Christina Nunes de Palmer Paixão<sup>2</sup> <https://orcid.org/0000-0001-7513-2567>, Universidade Federal Fluminense – Niterói (RJ), Brasil. E-mail: [izabelpaixao@id.uff.br](mailto:izabelpaixao@id.uff.br)

PhD Claudio Cesar Cirne dos Santos Pessanha<sup>3</sup> <https://orcid.org/0000-0001-8376-1830>, Universidade Federal Fluminense – Niterói (RJ), Brasil. E-mail: [claudiocirne@id.uff.br](mailto:claudiocirne@id.uff.br).

PhD Caroline de Souza Barros <https://orcid.org/0000-0002-4678-3093> Universidade Federal Fluminense – Niterói (RJ), Brasil. E-mail: [carolsb.uff@gmail.com](mailto:carolsb.uff@gmail.com)

Kíssila Rabelo<sup>4</sup> <https://orcid.org/0000-0001-7579-7788>, Laboratório de Ultraestrutura e Biologia Tecidual (LUBT), Departamento de Histologia e Embriologia, Universidade Estadual do Rio de Janeiro, UERJ. RJ, Brasil. E-mail: [kissila@gmail.com](mailto:kissila@gmail.com)

Maurício de Souza Leão<sup>5</sup> <https://orcid.org/0000-0002-1628-0786>, Engenharia Clínica Hospital Universitário Antônio Pedro – HUAP- Universidade Federal Fluminense – UFF, E-mail: [msleao@id.uff.br](mailto:msleao@id.uff.br)

MD.PhD. Hugo Boechat Andrade<sup>6</sup> <https://orcid.org/0000-0001-6781-6125>, Universidade Federal Fluminense – Niterói (RJ), Brasil. E-mails [hugoboechat@id.uff.br](mailto:hugoboechat@id.uff.br)

MD. PhD Ingrid Antunes da Silva<sup>7</sup> <https://orcid.org/0000-0003-0905-0197>, Universidade Federal Fluminense – Niterói (RJ), Brasil. E-mail: [ingrid\\_antunes@id.uff.br](mailto:ingrid_antunes@id.uff.br)

Christina Thereza Machado Bittar<sup>8</sup> <https://orcid.org/0000-0003-2839-9677>, E-mail: [chbittar@gmail.com](mailto:chbittar@gmail.com)

José de Carvalho<sup>9</sup> <https://orcid.org/0000-0002-8058-8400>, Laboratório de Ultraestrutura e Biologia Tecidual (LUBT), Departamento de Histologia e Embriologia, Universidade Estadual do Rio de Janeiro, UERJ. RJ, Brasil E-mail: [jjcarv@gmail.com](mailto:jjcarv@gmail.com)

Aline Gissele Azevedo Ferreira Goulart<sup>10</sup> <https://orcid.org/0009-0004-2010-0233>,  
Universidade Federal Fluminense – Niterói (RJ), Brasil. E-mail:  
[alinegissele@id.uff.br](mailto:alinegissele@id.uff.br)

Lucas Gabriel Cabrera Campos<sup>11</sup> <https://orcid.org/0009-0002-5271-7882>, Universidade  
Metropolitana de Santos SP – UNIMES E-mail: [lu12345cas@hotmail.com](mailto:lu12345cas@hotmail.com)

MD. Adriel Chihyung Chung Campos<sup>12</sup> <https://orcid.org/0000-0002-5120-4367> Universidade  
Federal de Integração Latino-Americana UNILA – Foz do Iguaçu (PR), Brasil. E-  
mail: [adriel\\_20\\_08@hotmail.com](mailto:adriel_20_08@hotmail.com)

MD. PhD. Mauro Romero Leal Passos<sup>13</sup> <https://orcid.org/0000-0002-6183-7985> Universidade  
Federal Fluminense – Niterói (RJ), Brasil. E-mail: [maurodst@gmail.com](mailto:maurodst@gmail.com)

### **Address for correspondence**

MD. PhD. Wilma Nancy Campos Arze. ORCID: <https://orcid.org/0000-0002-2620-0620> Universidade Federal de Integração Latino-Americana UNILA – Foz  
do Iguaçu (PR), Brasil E-mail: [wilma.arze@gmail.com](mailto:wilma.arze@gmail.com) Tel:55 (45) 99118-8828

MD. PhD. Mauro Romero Leal Passos ORCID: <https://orcid.org/0000-0002-6183-7985> Chefe do Setor de Doenças Sexualmente Transmissíveis do  
Departamento de Microbiologia e Parasitologia, Instituto Biomédico,  
Universidade Federal Fluminense, Niterói, Rj, Brasil. E-mail:  
[mauroromero@id.uff.br](mailto:mauroromero@id.uff.br) – [maurodst@gmail.com](mailto:maurodst@gmail.com) -Tel: +55 (21) 99888 -2897.