

HUMAN PAPILLOMAVIRUS DETECTION BY THE HYBRID CAPTURE ASSAY IN THE MALE GENITAL TRACT

DETECÇÃO DE PAPILOMAVÍRUS HUMANOS PELA TÉCNICA DE CAPTURA DO HÍBRIDO NO TRATO GENITAL MASCULINO

Fernanda N Carestiato¹, Katia C Silva², Pedro HP Prudente³, Licinio E Silva⁴, Mariza Botelho⁵, Ledy HS Oliveira⁶, Silvia MB Cavalcanti⁶

ABSTRACT

Introduction: the Human Papillomavirus infection is the most disseminated viral sexually transmitted disease worldwide. Most part of the cases of male HPV infections are subclinical, and this conditions permit the dissemination of this virus silently. **Objectives:** To study the genital infections caused by the HPV, determining the prevalence of HPV types in male patients, attended at Laboratório Sergio Franco of the State of Rio de Janeiro, in 2001 and 2002. **Methods:** 1063 samples of male patients had been submitted the examinations for detection of HPV for the Technique of Hybrid Capture. Using the kit Digene (USA) Hybrid Capture® II HPV Test. **Results:** Among all the samples analyzed, 281 (26,4%) were positive to HPV, and 782 (73,6%) were negative to HPV. In positive samples 108 were infected by high-risk group (Group B), 97 by low-risk group (Group A), and 76 were infected with both groups. The medium age of the participants was 30 years. **Conclusion:** This result showed a high prevalence of HPV in men when compared to the rates encountered in developed countries. Our study considered that HCAII is a reliable test to detect HPV in male samples and this conduct contributes to prevent the dissemination of this virus to women, where the HPV exerts their potential of malignant transformation most efficiently.

Keywords: Human Papillomavirus, Hybrid capture, penis

RESUMO

Introdução: a infecção pelo papilomavírus humano é a doença sexualmente transmissível viral mais disseminada mundialmente. A maioria dos casos de infecção masculina são subclínicos e esta condição permite a disseminação silenciosa desse vírus. **Objetivos:** estudar as infecções genitais causadas pelo HPV, determinando a prevalência dos tipos de HPV nos pacientes masculinos atendidos no Laboratório Sergio Franco do Estado do Rio de Janeiro, em 2001 e 2002. **Métodos:** 1063 amostras de pacientes masculinos foram submetidas a exame de detecção de HPV pela Técnica de Captura do Híbrido. Usando o *kit* da Digene (USA) Hybrid Capture® II HPV Test. **Resultados:** entre as amostras analisadas, 281 (26,4%) eram positivas para HPV, e 782 (73,6%) eram negativas para HPV. Das amostras positivas, 108 estavam infectadas pelo HPV do grupo de alto-risco grupo B) e 97 estavam infectadas pelo grupo de baixo-risco (grupo A), e 76 estavam infectadas pelos dois grupos. A média de idade das participantes foi de 30 anos. **Conclusão:** este resultado mostrou uma alta prevalência de HPV em homens quando comparados aos níveis encontrados em países desenvolvidos. Nosso estudo considerou a HCAII um teste confiável para detectar o HPV em amostras masculinas e esta conduta contribui para prevenir a disseminação deste vírus para as mulheres, nas quais o HPV exerce seu potencial maligno de transformação mais eficientemente.

Palavras-chave: Papilomavírus humanos, captura do híbrido, pênis

ISSN: 0103-0465

DST – J bras Doenças Sex Transm 17(1): 62-65, 2005

INTRODUCTION

In worldwide literature HPV infections in men have not received much attention. Perhaps because HPV infections do not have as serious consequences for men as they have for women¹. But the high prevalence pointing it as the most disseminated viral

sexually transmitted disease^{2,3} and the confirmation of the HPV as the etiological agent of cervical cancer⁴, increased the interest in male HPV infections, among which the majority of cases are subclinical and remain invisible to naked eye. These conditions permit HPV to spread silently⁵. In fact, several studies have attempted to demonstrate that even in the absence of clinical lesions the male urethra is a reservoir for HPV with prevalence of HPV detection ranging from 17% to 50%⁶.

Epidemiological data show that nearly 50% of sexually active women and men between the 15th and 49th year of age present infections with at least one, sometimes several genital HPV types⁷.

In men, productive HPV infection can result in simple condyloma acuminata, giant condyloma, or Buschke-Löwenstein

¹Mestre em Patologia experimental –UFF

²Aluna do Curso de Mestrado de Ciências Médicas - UFF

³Aluno de Biomedicina da UFF, Bolsista de Iniciação Científica – CNPq

⁴Prof. Adjunto do Departamento de Estatística, Especialista em Matemática Aplicada – UFF

⁵Gerente Técnica do Laboratório Sergio Franco.

⁶Prof. Adjunta do Departamento de Microbiologia e Parasitologia, UFF

Finnantial supprot from Conselho Nacional de Pesquisa – CNPq

tumor, mainly caused by HPV genotypes 6 and 11. But visible genital warts are, however, detectable only in about 1% of this population, representing only the top of the HPV iceberg³. HPV-associated penis intraepithelial neoplasia represent the great majority of the cases but are inconspicuous lesions caused by high risk HPV types, specially HPV 16 and 18, showing histologically low, moderate, or severe dysplasia (PIN grades 1, 2 and 3)⁷. Less frequently, high risk HPV infection can progress to penile carcinoma, also associated to HPV 16 and 18 in 30 to 50% of the cases⁸.

Penile cancer is a rare tumor and has high incidence in older men. It is typically a disease of middle-aged to older men, most commonly affecting those between 50 and 70 years of age⁹. The prevalence of penile carcinoma has geographically heterogenic distribution¹⁰ ranging from 15% to 71%, depending on the detection method and the tumor type studied¹¹. In Europe and USA it is an uncommon disease, with an annual incidence of 0.3-1,5 per 100.000 inhabitants. That represents 0,3-0,5% of all malignancies in the male population of the USA. In developing countries of Africa, South America and of the Far East, however, the incidence is much higher than in Europe and the USA, reaching 10-22% of all male malignancies⁷. In Brazil, it represents 2% of all male cancer, and is present more frequently in regions North and Northeast (5.5% at 16%) and 1% at 4% in South Southeast regions¹². Epidemiological evidences suggest that presence of HPV infection, phimosis, poor genital hygiene, earlier age at first sexual intercourse, a history of multiple sexual partners, chronic inflammation, smoking, and other STIs are risk factors for penile cancer^{1,7,13}.

Studies revealed that man can be regarded as the epidemiological source of female infection and that HPV-associated lesions are detected in 50% to 70% of male partners of infected women⁶, partners of men having penile cancer showed cervical cancer incidence eight times higher risk of developing penile cancer, and when both partners have HPV DNA, the incidence of the same virus group is small, but is larger in the group of women having CIN⁸. These data can explain the vicious circle of infection and recurrence in female and in failure in treatment, due to reinfection by male partners presenting subclinical HPV lesions.

There is no specific antiviral compound available so far that is able to eliminate HPV completely⁷. Medical therapies for HPV including: Podophyllin treatment, Trichloroacetic acid, Imiquimod, Interferon, and other substances³. The treatment of oncogenic HPV associated intraepithelial and invasive squamous cell neoplasias should be primarily surgical (laser, electrocauter)^{3,7,13}. Preventive measures should be considered in order to avoid penile carcinoma, including prevention of phimosis, treatment of chronic inflammatory conditions and precece detection and treatment of oncogenic HPV infection⁷.

No practical sampling technique has been established to easily identify HPV infection in the penis, relatively few cells are recovered by swabbing the urethra or the glands penis¹⁴. Besides, one of the most common diagnostic tools utilized from penile lesions is the peniscopy, but no uniformly accepted peniscopic criteria have been elaborated for the HPV-associated aceto-white lesions in the literature^{5,8}. Therefore, an acetic acid reaction is no speci-

fic indicator of HPV infection, consequently many false-positive tests can be found in low-risk populations. Like the study from Rosenblatt⁸ that found HPV DNA in only 43% of the cases diagnosed as HPV by peniscopy. Cavalcanti *et al*¹⁵ showed a prevalence of HPV infection by in situ hybridization of 67.1%. HPV DNA was detected in 75% of condilomata and papules, 65% of acetowhite lesions and 50% of carcinomas. The agreement between hybridization and peniscopy was fairly good (69.6%), and between the hybridization and cytology was 67.8%. The diagnosis of condilomata and papules was easily achieved, but it was not true for acetowhite lesions, related to diverse pathologies and source of misdiagnosing of penile lesions.

HPV detection has generally been conducted by southern blot and PCR methods. But neither research assays nor commercial kits (dot blot or in situ hybridization) have shown to be adequate for clinical use. An assay for routine clinical use requires reliable and accurate detection of the broad range of pathogenic HPV types infecting the genital tract¹⁶. Recently developed, the second generation of Hybrid Capture System HPV DNA detection test from Digene Diagnostics (Silver Spring, Md.) is a non-radioactive, relatively rapid, liquid hybridization assay designed to detect 18 HPV types divided into high-risk and low-risk groups. HPV DNA test might be an useful tool to indicate potential premalignant lesions in male patients as well as to elucidate inconclusive cases obtained by peniscopy. It is also necessary to consider the importance of detecting subclinical HPV lesions, since men are the principal epidemiological source of HPV infection for the female genital tract, where the HPV exerts their potential of malignant transformation most efficiently¹⁷.

Hence, the aim of our study was to investigate the prevalence of HPV infection in male genital tract in order to determine the prevalence of high-risk oncogenic infections by hybrid capture assay to obtain subsidies to understand male infection importance for female infection and to help preventing oncogenic infections to become malignant processes. For this we proceeded to a survey of the penile samples from male patients attended at Laboratório Sérgio Franco, Rio de Janeiro, Brazil.

METHODS

Specimens: 1063 penile samples of male patients with ages between 16–96 years, attended at Laboratório Sérgio Franco, Rio de Janeiro, Brasil, in 2001 and 2002. The samples were collected and transported in Digene Specimen Transport Medium (Digene Diag, Md).

Hybrid Capture Assay: The assay kit used was the Digene Hybrid Capture® II HPV Test (Microplate System). The kit contains two pools of probes with the more commonly types in each risk-group to develop cancer: Pool A with low-risk types (HPV 6, 11, 42, 43 and 44) and Pool B with high-risk types (HPV 16, 18, 31, 33, 35, 39, 45, 51, 52, 56, 58, 59 and 68). According to the kit protocol, specimens were treated with sodium hydroxid to hydrolyze specimen RNA and denature the DNA. The liberated single strand DNA was hybridized in solution with a RNA probe mix consisting of the high-risk or the low-risk HPV types. Each

reaction mixture, containing any RNA-DNA hybrids that formed, was transferred to a capture tube coated with antibodies to the hybrids, immobilizing them. Bound RNA-DNA hybrids were then reacted with an alkaline phosphatase-conjugated antibody directed against the hybrids. Unreacted material was removed by washing, and a dioxetane-based chemiluminescent compound, Lumi-Phos 530, was added as a substrate for alkaline phosphatase. The light produced by ensuing reaction was measured by a Luminometer. Light measurements were expressed as relative light units (RLUs). As a negative control, sonicated herring sperm DNA in Digene transporting medium (100g/ml) was used. Triplicate specimens of HPV 16 or HPV 11 DNA at 10pg/ served as the positive controls for high-risk and low-risk probes, respectively.

In the final of the process the light produced by the reaction was measured in a Luminometer. And these measurements were expressed as relative light units (RLUs). Had been used controls negatives and positives (for high-risk and low-risk probes) in triplicate. All RLU measurements for specimens were divided by the mean RLU of the three appropriate positive controls (PCs) to give a ratio of specimen RLU/PC. A ratio of 1.0 or greater was regarded as positive for HPV DNA, and a ratio of less than 1.0 was regarded as negative.

RESULTS

Our study analyzed 1063 samples from male patients with ages varying between 16 and 96 years. The medium age of the participants was 30 years. Among this samples 281 patients were positive to HPV by Hybrid Capture Assay, and 782 were negative to HPV. That represented 26,4% of the patients infected by

some HPV type. In positive samples 108 were of high-risk group (Group B), 97 of low-risk group (Group A), and 76 were positive for both groups. In the positive cases 184 (65,5%) patients were infected by oncogenic HPV, including simple infections (Positive B) and mixed infections (Positive A and B) (**Table 1**).

The **graphic 1** shows the correlation between positive and negative HCA II and the distribution for the age bands. We can observe in this graphic that patients with age between 20 to the 30 years had the greater prevalence of HPV infection, and a reduction on the numbers cases occurs according to the increase of the patient's age.

DISCUSSION

The results showed 26.4% patients infected by HPV, with the highest prevalence among young men. Of these, more than 65% men were infected with oncogenic HPV types. Rosenblatt⁸ obtained 16.7% de DNA HPV in men, among which 46.7% were low-risk and 53,3% were righ-risk. These results might indicate a higher risk of cancer progression and in fact Brazil presented a higher incidence of genital cancer¹⁸.

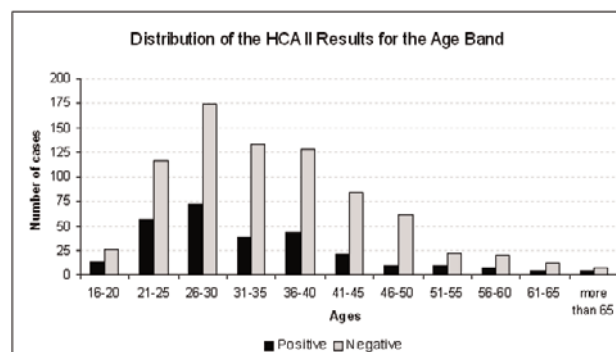
The band of major prevalence of HPV infection was the 20-30 years of age. This band of age coincided with the summit sexual activity of men. The decrease of the rate of infection observed in the increase of the age can be explained for the reduction of sexual activity and, probably, they were persistent infections.

The analysis of male samples showed HPV profile of infection not much similar to obtained in a survey of female cases conducted in the year of 2001¹⁹. The number of HPV positive cases in male study is smaller than the female study, with a higher number of infections caused by low-risk HPV types in men compared to

Table 1 - Results from Hybrid Capture Assay in penile lesions

Hybrid Capture HCA II	Group A	group B	Group A + b	Total
NUMBER OF PATIENTS	97	108	76	281
(%)	34,5%	38,4%	27,1%	26,4%

Graphic 1 - Distribution of HCA II results according to the age bands of male patients



women. Primarily, the reduced number of infected male patients in relation to the female patients can be explained by the different kind of epithelial tissue that covered the penis and the uterine cervix. The penile shaft and the outer surface of the foreskin are covered by a keratinized stratified squamous epithelium that provides a natural protective barrier against HPV infection²⁰. Besides that, in woman, the epithelium is non-keratinized in most part of the cervix, where is the squamous-columnar junction, called the transformation zone, which exposes the epithelium to HPV infection. One explanation for the frequent infections of low-risk types in men is the different cell tropism characteristic in HPV types, associated to site specific restrictions.

It is necessary to emphasize that the two groups came from the same geographical region and attended at the same period at the same Laboratory. Hence, we assume that they are very similar populations sharing socio-economic conditions and customs. We question if the male cases are intimate related to female infection, being the reservoir for their partners and turning difficult to control these Sexually Transmitted Disease Epidemics.

In fact, Neves and colleagues²¹ study proposed that HPV infection and natural history conducting to penile cancer is a multifactorial process similar to cervical squamous cell carcinoma. Fernandes¹⁰ also showed important parallels to vulvar and cervical cancer with penile cancer. And still, the studies from Rubin¹¹, and Gross & Pfister⁷, found a prevalence of HPV-DNA in penile carcinoma about 40-45%, which is similar to the detection rate of HPV-DNA in vulvar carcinoma (50%), with the histological subtypes of penile neoplasia identical to those described at the vulva

There are extensive evidence reinforcing the use of a HPV DNA detection test, such as the HCA, because that HPV types are not always absolutely consistent with the clinical type of HPV-associated genital lesion, showing diverse prevalence rates in different countries and cities: high-risk HPV types, such as 16 and 18, can also be isolated from "benign" HPV-associated genital lesions more than is usually expected². These oncogenic infected benign lesions may represent a risk for the female population, exposed to high-risk viruses, presenting a benign profile of infection in their sexual partners. These variations in virological data have implications in vaccine testing, choice of diagnostic methods, and epidemiological studies involving disease control²¹.

CONCLUSION

Finally, taking into consideration these aspects above cited, we consider that HPV detecting and typing of male genital HPV lesions are an important part of the diagnostic procedure, treatment, and follow-up of patients and also for cervical and penile cancer prevention strategies.

REFERENCES

1. Castellsagué X, Ghaffari A, Daniel RW, Bosch FX, Muñoz N and Shah KV. Prevalence of Penile Human Papillomavirus DNA in Husbands of Women with and without Cervical Neoplasia: A Study in Spain and Colombia. *J Infect Dis* 1997; 176: 353-361.
2. Skerlev M, Grce M, Skerlev MS, Hunsnjak K, and Lipozencic J. Human Papillomavirus male genital Infections: Clinical variations and the Significance of DNA Typing. *Clinics in Dermatology* 2002; 20: 173-178.
3. Gilbert SM, Lambert SM, and Weiner D. Extensive Condylomata Acuminata of the Penis: Medical and Surgical Management. *Infect Urol* 2003; 16 (3): 65-76.
4. Muñoz N, Bosch X, Sanjose S, Herrero R, Castellsagué X, Shah KV, Snijders PJF, and Meijer CJLM. Epidemiologic classification of human papillomavirus types associated to cervical cancer. *N England J Med* 2003; 348: 518-527. 5- Hippeläinen MI, Syrjänen S, Hippeläinen MJ, Saarikoski S, and Syrjänen K. Diagnosis of genital human papillomavirus (HPV) lesions in the male: Correlation of peniscopy, histology and in situ hybridization. *Genitourin Med* 1993; 69: 346-351.
6. Aynaud O, Ionesco M, and Barrasso R. Cytologic Detection of Human Papillomavirus DNA in Normal Male Urethral Samples. *Urology* 2003; 61: 1098-1101.
7. Gross G & Pfister H. Role of human papillomavirus in penile cancer, penile intraepithelial squamous cell neoplasias and in genital warts. *Med. Microbiol Immunol* 2004; 193: 35-44.
8. Rosenblatt C, Lucon AM, Pereyra EAG, Pinotti JA, Arap S, and Ruiz CA. HPV prevalence among partners of women with cervical intraepithelial neoplasia. *Int J of Gynecol and Obstet* 2004; 84: 156-161.
9. Pow-Sang MR, Benavente V, Pow-Sang JE, Morante C, Meza L, Baker M, and Pow-Sang JM. Cancer of the penis. *Cancer Control* 2002; 9(4): 305-314.
10. Fernandes MGM, Ferreira FVA, Ferreira SNH, Lima SMS, Filho FDR, Ribeiro AVMF, Rabenhorst SH, Mesquita SM, Ferreira G, and Amorim LHM. MIB1 and p53 in penile intraepithelial and invasive squamous HPV related lesions. *Rev Bras de Cancerol* 2002; 48 (1): 29-37.
11. Rubin MA, Kleter B, Zhou M, Ayala G, Cubilla AL, Quint WGV, and Pirog EC. Detection and Typing of Human Papillomavirus DNA in Penile Carcinoma. Evidence for Multiple Independent Pathways of Penile Carcinogenesis. *Am J of Pathol* 2001; 159 (4):1211-1218.
12. Gil AO, Pompeo, ACL, Goldstein PJ, Saldanha LB, Mesquita JLB, and Arap S. Analysis of the Association Between Human Papillomavirus With Penile carcinoma. *Bra J of Urol* 2001; 27 (5): 461-468.
13. INCA Instituto Nacional do Câncer .Ministério da Saúde. Câncer de pênis. 2004 Disponível em: http://www.inca.gov.br/conteudo_view.asp?id=338. Acessado em: 13/12/2004
14. Bleeker MCG, Hogewoning CJA, van de Brule AJC, Voorhost FJ, van Andel RE, Risse EKJ, Starink TM, and Meijer CJLM. Penile lesions and human papillomavirus in male sexual partners of women with cervical intraepithelial neoplasia. *J Am Acad Dermatol*. 2002; 47 (3) 351-357.
15. Cavalcanti SMB, Gouvêa T, Passos MRL, and Oliveira LHS. Diagnóstico de lesões causadas por papilomavirus humanos no trato genital masculino: correlação da escopia genital, histologia e hibridização in situ. *Rev Bras Patol Clin* 1994; 30 (3): 120-124.
16. Schiffman MH & Brinton LA. The epidemiology of cervical carcinogenesis. *Cancer* 1995; 76: 888-901.
17. Cox JT, Lorinczy AT, and Schiffman MH. Human Papillomavirus testing Hybrid Capture appears to be useful in triaging women with a cytological diagnosis of ASCUS. *Am J Obstet Gynecol* 1995; 172: 946-54.
18. Segi M. Graphic presentation of cancer incidence by site and by area and population. Segi Institute for Cancer Epidemiology Nagoya; 1997.
19. Carestiato FN, Carvalho MOO, Ribeiro MO, Marinho M, Barbosa FM, Silva LE, Dimetz T, Oliveira LHS, and Cavalcanti SMB. Estudo das Infecções por Papilomavirus Humanos em Pacientes do Sexo Feminino Detectados pela Técnica de Captura do Híbrido: Levantamento dos Casos. *DST J bras Doenças Sex Transm* 2002; 14(12): 9-12.
20. Castellsagué X, Bosch FX, Munoz N, Meijer CJLM, Shah KV, Sanjosé S, Eluf-Neto J, Ngelangel CA, Chichareon S, Smith JS, Herrero R, and Franceschi S. Male circumcision, penile human papillomavirus infection, and cervical cancer in female partners. *N Engl J Med* 2002; 346 (15): 1105-1112.
21. Neves D, Camara GNL, Alencar TR, Cruz MR, Martins CRF, and Carvalho LGS. Prevalence of Human Papillomavirus in Penile Carcinoma. *Bra J of Urol* 2002; 28 (3): 221-226.

Correspondence:

SILVIA MARIA BAETA CAVALCANTI

Lab. Virologia - Depto de Microbiologia e Parasitologia - Instituto Biomédico- UFF
Rua Ernani Melo, 101. Centro,
Niterói, RJ. Brasil - CEP 24210-030.
E-mail : silviabc@ism.com.br

Recebido em: 20/02/05

Aprovado em: 18/03/05